

CASE REPORT

 Open Access

## Normal pregnancy outcome after emergency ovarian cystectomy for ovarian cyst torsion in the first half of pregnancy: A case report

Sylvester Onuegbunam Nweze, Ogechukwu Crescent Abugu, Emmanuel Ikechukwu Okolie, Malachy Nwaeze Ezenwaeze, Ugochukwu Daniel Umekwe, Kelvin Emeka Ortuanya, Fredrick Ikenna Awkadigwe, Perpetual Kelechi Enyinna, Chimdalu Ubaka Omeje  
Department of Obstetrics and Gynaecology, ESUT Teaching Hospital Parklane, Enugu, Nigeria

### ABSTRACT

**Background:** Ovarian cysts are fluid-filled sacs on the ovary, with a global incidence of 16.7% and higher prevalence in women of reproductive age. Complications include torsion, hemorrhage, rupture, or infection. Torsion is the most common and serious complication often presenting in the first trimester of pregnancy.

**Case Presentation:** A 24-year-old primigravida presented with severe lower abdominal pain at 10 weeks gestation. She was diagnosed with a torsioned ovarian cyst coexisting with an intrauterine pregnancy. Emergency laparotomy with ovarian cystectomy was performed, and she had a normal pregnancy outcome.

**Discussion:** The majority of ovarian cysts in pregnancy are functional and rarely malignant. Diagnosis can be incidental through prenatal ultrasound. Ovarian torsion commonly presents with abdominal pain, nausea, and vomiting. Ultrasound is the preferred diagnostic tool, with magnetic resonance imaging reserved for inconclusive cases or for precise characterization of larger masses. Surgical care with cystectomy and detorsion is the most common treatment option.

**Conclusion:** Torsion of an ovarian cyst in pregnancy poses challenges due to the need to balance the safety of both mother and child. Surgery is the recommended treatment modality for ovarian cyst torsion presenting with acute abdomen.

### ARTICLE HISTORY

Received July 30, 2024

Accepted September 02, 2024

Published September 02, 2024

### KEYWORDS

Ovarian cyst; torsion; adnexal mass; pregnancy; ovarian cystectomy

### Introduction

An ovarian cyst is the presence of a fluid-filled sac on the ovary. Its global incidence is about 16.7% and it is more prevalent in women of reproductive age [1]. Ovarian cysts can occur in pregnancy with an incidence of about 5 per 10,000 pregnancies [2]. When coexisting with pregnancy, it is more likely to occur in the first and second trimester of pregnancy [3]. Ovarian cysts can be complicated by torsion, hemorrhage, rupture, or infection [4]. Ovarian cyst torsion is a gynecological emergency that is said to have occurred when the cyst with or without the affected ovary partially or totally rotates around its vascular axis or pedicle. Occurring in about 25% of

cases, torsion is the most common and serious complication of ovarian cysts typically presenting in the first trimester [4].

What leads to torsion of the ovaries is poorly understood but there are predisposing factors which include ovarian size >5cm as seen in about 80%. The other 20% can be accounted for by factors such as pregnancy, dermoid cyst, history of abdominal surgery, high mobility cyst, presence of long pedicle, and history of tubal ligation [1].

Torsion of the ovarian cyst presents with nonspecific symptoms which are often misdiagnosed with other acute abdominal conditions such as ectopic pregnancy, pelvic inflammatory disease, ruptured

**Contact** Emmanuel Ikechukwu Okolie ✉ okolieemmanuel8@gmail.com 📍 Department of Obstetrics and Gynaecology, ESUT Teaching Hospital Parklane, Enugu, Nigeria.

ovarian cyst, appendicitis, and so on [3]. Sudden onset of abdominal pain which is usually one-sided, coinciding with the site of the affected ovary is the commonest presenting symptom of ovarian torsion [3]. Other symptoms include nausea and vomiting [2,3]. A tender cystic mass can be picked up during examination which is different from the uterus [2]. Ultrasound is very helpful in making the diagnosis, in addition to a good history and physical examination.

Treatment can be quite challenging in pregnancy. This is because the safety of both the mother and the fetus is put into consideration. Options of treatment include expectant or surgical management. Although found to be the most favorite option by most practitioners, laparoscopic management compared to open surgeries can be quite challenging due to the enlarged uterus [3]. However, it is associated with decreased postoperative pain, best postoperative course, lower narcotic use, shorter hospital stay as well as lower risk of infections, with no significant difference in fetal outcome [4]. While cystectomy and detorsion were the most commonly performed procedures (29.06%) followed by salpingo-oophorectomy (27.32%) and solitary detorsion (18.32%), other procedures that can be performed include oophorectomy, cystectomy, ovariopexy, or cyst aspiration and drainage [3,5,6]. A study conducted among women with ovarian torsion and functional ovarian cysts showed that management with detorsion alone is associated with a higher recurrence rate compared to those who had detorsion alongside aspiration and drainage (14% vs. 0) [5]. Expectant or conservative management is uncommon in ovarian cyst torsion and was reported in just 2.99% of 662 pregnant women with adnexal torsion included in a systematic review [3].

This case report discusses a 24-year-old primigravida who was diagnosed with a torsioned ovarian cyst coexisting with intrauterine pregnancy at 10 weeks gestational age and had a normal pregnancy outcome following emergency laparotomy with ovarian cystectomy.

### Case Presentation

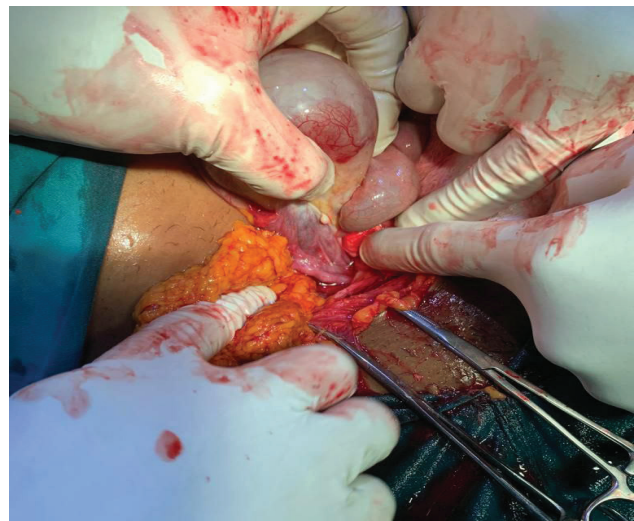
A booked 24-year-old primigravida presented with a 5-hour history of severe lower abdominal pain that was more on the right side. It was colicky in nature, waxing and waning with radiation to the thigh. There was an associated history of nausea with 2 episodes of vomiting prior to presentation. She refuted other symptoms such as fever, bleeding

per vaginam, abnormal vaginal discharge, weakness, or shoulder tip pain. She admitted to having attended routine antenatal care supervised by midwives and an obstetrician and had an early point-of-care ultrasound scan in which a right ovarian cyst was detected. She had no history of previous gynecological diseases, previous surgeries, or any chronic medical conditions such as hypertension, diabetes mellitus, or asthma.

Examination revealed a hemodynamically stable woman who was not pale, acyanotic, or anicteric but had tenderness at the right lower abdomen.

Laboratory tests showed no abnormalities. An ultrasound scan revealed a right ovarian cyst measuring 6.45 cm × 5.80 cm × 4.32 cm with a positive whirlpool sign coexisting with normal intrauterine pregnancy of 10 weeks gestational age; the contralateral adnexa was unremarkable and there was no free fluid in the pouch of Douglas. An impression of a torsioned right ovarian cyst coexisting with in-utero singleton pregnancy at 10 weeks gestation was made.

An emergency laparotomy under spinal anesthesia was done and careful right ovarian cystectomy with detorsion was performed with minimal handling of the uterus and the adnexae (Fig. 1). Intraoperative findings were that of a cystic mass that measured 7 cm × 6 cm × 5 cm with a single twist around the ovarian pedicle. The patient's postoperative condition was satisfactory and she was discharged on the third day after surgery. Histopathologic examination of the intraoperative specimen reported a benign ovarian serous cystadenoma, and the patient was reassured based on the report.



**Figure 1.** Intraoperative findings revealed ovarian cyst torsion.

The pregnancy was closely monitored and carried to full-term ending in a normal vaginal delivery of a female baby.

## Discussion

The majority of the cysts in the ovary in pregnancy are functional cysts and rarely do you find malignant ovarian cysts during pregnancy [5,6,7]. Serous cystadenoma, benign cystic teratogenic, and functional cysts are the frequently diagnosed benign ovarian masses during pregnancy [8]. Diagnosis can be incidental with prenatal ultrasound as it is mostly asymptomatic [4,6]. Possible complications that can arise include torsion, rupture, infection, malignant transformation, cyst impaction in the pelvis leading to urine retention, obstructed labor, and fetal malpresentation [4,7]. The patient in our case had right ovarian cyst torsion which occurred at 10 weeks gestational age.

Ovarian torsion more commonly occurs on the right, and the majority of the time, it presents more in the first and second trimester, as seen in the case we presented, and rarely in the third trimester [7]. Clinically, patients with ovarian cyst torsion will complain of abdominal pain (>88%), nausea and vomiting (59%–85%), fever (20%), and abnormal bleeding from the uterus (1).

Torsioned ovarian cysts can be diagnosed using radiological modalities such as ultrasound. The presence of whirlpool signs, ovarian enlargement, ovarian edema, and so on, on ultrasound, makes the diagnosis more likely [1]. Although the systematic review by Didar et al. [3] showed that reduced flow on Doppler was found in a little over half of the patients with ovarian torsion, the usefulness of Doppler ultrasound in the diagnosis of ovarian torsion has remained controversial [3,6]. This is because while the diagnosis of torsion is suggested by absent or diminished flow by Doppler studies, it cannot be ruled out by the presence of normal flow [6]. Despite its shortcomings, the sensitivity and specificity remain as high as 92% and 90%, respectively [1]. Due to its safety, ultrasound is the most frequently used modality for initial assessment with good sensitivity and specificity in defining the morphology of adnexal masses [4]. However, magnetic resonance imaging with its higher sensitivity and specificity for adnexal masses compared to ultrasound may come in handy in events of inconclusive ultrasound examination or when more precise characterization of bigger masses that ultrasound cannot easily visualize is needed [4].

During pregnancy, there are some factors that predispose to torsion of the ovarian cysts. These include anatomical changes in the pelvic organs, increase in ovary or cyst size, sudden physical movement, uterine contraction as well as bowel movement [1].

At all times, the clinician is faced with the hard decision to treat or not to treat as they weigh the risks and benefits of treatment to both the mother and the baby. Despite the controversies in the management of adnexal masses in pregnancy without symptoms, the most recommended approach is conservative or expectant management which involves monitoring with ultrasound, carbohydrate antigen-125 (CA 125), beta hCG, or alpha fetoprotein (AFP) [1,6]. The recommendation for elective surgery in the past to prevent ovarian torsion was based on studies by Hess and colleagues who found a higher incidence of adverse outcomes in emergent surgery for torsion compared with elective surgery (40% vs. 2%) [6]. However, recent studies have demonstrated lower complication rates with emergent surgery and further showed the risk of ovarian torsion in patients with incidental adnexal masses in pregnancy to be low enough to justify expectant management [6].

For symptomatic patients whose cysts fail to resolve spontaneously or become complicated by torsion presenting with acute abdomen, surgery is recommended [1,3]. Where possible, such surgeries are best performed in the second trimester when the risk of miscarriage is lowest [1,3]. If surgery is done in patients whose gestational age is less than 10 weeks, there is a high risk of pregnancy loss. This is because removal of the cyst, and/or the ovary may reduce progesterone concentration which is vital in the maintenance of pregnancy. Therefore, such candidates are subject to progesterone supplementation until 12 weeks gestational age [1]. Generally, spontaneous abortion, fetal growth restriction, preterm labor, and neonatal death are some of the potential risks associated with surgery for adnexal masses during pregnancy [6]. Despite these risks, surgical management is indicated for any symptomatic adnexal mass, as in cases of torsion, irrespective of the gestational age [6].

## Conclusion

The management of torsion of the ovarian cyst in pregnancy can be challenging especially because the safety of both mother and child is at risk while trying to manage the pathology. There is a need

for a high index of suspicion among clinicians for ovarian torsion in pregnant women with incidental ovarian cysts as this will enable prompt diagnosis and timely treatment to avert complications.

Conservative management is recommended in asymptomatic patients with ovarian cysts coexisting with pregnancy, and surgery should be the last resort only for patients who are unresponsive to or unqualified for conservative management. However, surgical management is the treatment of choice for any symptomatic adnexal mass such as in ovarian cyst torsion irrespective of the gestational age.

### Conflict of interests

The authors declared that there was no conflict of interest regarding the publication of this article.

### Financial support

The authors declared that this study had received no financial support.

### Ethical issues

The authors had obtained permission before using patient data and images.

### References

1. Indirayani I, Nora H, Maharani CR, Jannah R, Febriana DMA, Mulya IC. A successful pregnancy complicated with ovarian cyst torsion in the first trimester. *Bali Med J* 2023; 12(2):2176–9; doi: 10.15562/bmj.v12i2.3951
2. Kolluru V, Gurumurthy R, Vellanki V, Gururaj D. Torsion of ovarian cyst during pregnancy: a case report. *Cases J* 2009 Dec 31; 2:9405; doi: 10.1186/1757-1626-2-9405
3. Didar H, Najafiarab H, Keyvanfar A, Hajikhani B, Ghotbi E, Kazemi S. Adnexal torsion in pregnancy: a systematic review of case reports and case series. *Am J Emerg Med* 2023; 65:43–52.
4. D'Ambrosio V, Brunelli R, Musacchio L, Del Negro V, Vena F, Boccuzzi G. Adnexal masses in pregnancy: an updated review on diagnosis and treatment. *Tumori* 2021 Feb; 107(1):12–6.
5. Melcer Y, Dvash S, Maymon R, Pekar-Zlotin M, Vaknin Z, Tzur T, et al. Torsion of functional adnexal cysts in pregnancy: aspiration and drainage are important in preventing recurrence. *Isr Med Assoc J* 2021 Jan; 23(1):48–51.
6. Graham III GM. Adnexal masses in pregnancy: diagnosis and management. *DSJUOG* 2007; 1(4):66–74.
7. Kuraishy A, Noor N, Mohsin Z. Twisted ovarian cyst in pregnancy: a case report. *Int J Reprod Contracept Obstet Gynecol* 2018; 7:3389–91.
8. Alleppanavar VK, Gomathy E. A rare case report of ovarian torsion in first trimester at tertiary care centre. *Indian J Obstet Gynecol Res* 2020; 7(3):455–7.