



Case Study

TONGUE IS AN UNUSUAL SITE OF ABSCESS DEVELOPMENT- AN EXPERIENCE OF TWO CASES

Mithilesh Kumar Pandey¹, Ashish Jaiswal¹, Shams Alam¹, Akhil Gupta¹

¹Department Of Surgery Government Medical College And Associated Dr. Susheela Tiwari Hospital Haldwani Distt Nainital Uttarakhand

Correspondence should be addressed to **Shams Alam**

Received January 15, 2016; Accepted January 26, 2016; Published February 10, 2016;

Copyright: © 2016 **Shams Alam** et al. This is an open access article distributed under the Creative Commons Attribution License, which permits unrestricted use, distribution, and reproduction in any medium, provided the original work is properly cited.

Cite This Article: Pandey, M., Jaiswal, A., Alam, S., Gupta, A.(2016). Tongue is an unusual site of abscess development- an experience of two cases. International Journal of Medicine & Health Research, 2(1).1-4

ABSTRACT

Tongue abscess is a rare entity, despite exposure to large number of potential pathogen, relatively resistant to infection. Here in this article we were discussed the two cases of tongue abscess in a young females, with their clinical presentation, differential diagnoses, management and a review of literature.

KEY WORDS: Tongue abscess, Glossal abscess, oral tongue, Tongue infection

KEY MESSAGES:

- i. Early clinical diagnoses of tongue abscess make good result.
- ii. Search the immune compromised state when diagnose the tongue abscess.
- iii. Needs immediate surgical drainage when conservative therapy failed or any deteriorating sign.
- iv. Selection of antibiotics and good oral hygiene make treatment successful.
- v. Prevention by improving the immunity with healthy nutrition and good oral hygiene.

INTRODUCTION

Acute infection of the tongue is rather rare in spite of the oral cavity full of innumerable sources of infection. Only few cases of tongue abscess have been reported in the English literature[1]

According to Combier and Murad[2]the frequency of such infections of the tongue is indeed, in marked contrast to that of infection of the tonsils, the floor of the mouth and the naso-pharynx. Tongue infection is the result of the interaction between the compromised local or systemic defence and pathogenic micro-organisms. The first line of

defence against an invading micro-organism is the mechanical barrier of the tongue mucosa. Once this first line of defence is breached and the host immune system is compromised, tongue infection can be severe and recalcitrant[3]

Clinical and ultrasound examination should establish the diagnosis, and treatment should be done by surgical incision and drainage[4]Tongue abscess should be considered, in all cases of acute swelling in the tongue especially when host defences are severely compromised[5]



CASE HISTORY 1

A female of 10 yrs age was presented with complaints of swelling on the right side of tongue since two weeks with tongue pain during chewing of food items and moderate to high grade fever was started one week ago. There was no history of trauma to the tongue and intake of steroid or any immunosuppressive drugs.

On oral examination, 2.5x2 cms size tense, tender soft tissue swelling was palpable on right side dorsum of the tongue in the anterior two third regions Fig.1[A].

The sub-mandibular lymph nodes were palpable on the right side. The systemic examination was unremarkable.

The laboratory investigations revealed her Hb 13.5 gm/dL, WBC count was 13500 cells/mm³ and ESR 25mm/hr, blood sugar 88mg/dl. HIV was non-reactive.

USG tongue shows hypoechoic mass lesion on right side dorsum of the tongue in the anterior two third regions. USG guided needle aspiration was done and sent for cellular smear study and culture sensitivity.

Smear shows rich cellularity comprising fair number of polymorph, few lymphocytes and macrophages Fig.1 [B]. The case was diagnosed as tongue abscess.

The patient was started on broad spectrum i.v antibiotics ceftriaxone, amikacin, clindamycin and analgesics.

The aspirate culture was group b streptococcus, sensitive to amoxicillin and amikacin. The antibiotic was changed after culture report. The fever was improved but the size of swelling and pain not responding to conservative therapy.

So that incision and drainage with curettage was done. The curettage material was sent for histopathological examination. The histopathology report was come out to be nonspecific chronic inflammatory granulation Fig. 1[C].

In postoperative period the patient was kept on intravenous antibiotics amoxicillin, amikacin and clindamycin for 1 week and then kept on oral antibiotics for 3 weeks.

The patient was followed up for 1 yrs and there was no recurrence.

CASE HISTORY 2

A female of 8 yrs age was presented with complaints of painless tongue swelling on the right side anterior part, for last one month. There was no history of, fever, trauma to the tongue, swallowing and chewing difficulty, and any intake of steroid or immune-suppressive drugs.

On oral examination a non-tender, soft, cystic swelling of size 2x1.5 cms was palpable on the right side of the tongue at anterior two third regions. The overlying mucosa was normal in colour Fig. 2[A]. There was no regional

lymphadenopathy. The systemic examination was unremarkable.

The haematological investigation revealed the WBC count 11,500/cumm, ESR 20mm/hr, blood sugar 97mg/dl. HIV was non-reactive. The USG of tongue suggested a well-defined hypoechoic mass lesion measuring 15.1x11.1mm with surrounding oedema seen in muscular plane on right lateral part of the dorsal surface Fig.2[B] on colour flow imaging no abnormal vascularity seen in mass lesion.

USG guided needle aspiration was done which shows pus material and sent for cellular smear study which revealed the inflammatory cells. Pus culture was showed Staphylococcus aureus and an anaerobes, sensitive to piperacillin, tazobactam and linezolid.

The patient was managed conservatively with intravenous piperacillin and clindamycin for one week along with anti-inflammatory then oral linezolid for two weeks. Antiseptic gargle was encouraged for regular use. The swelling was subsided in 3 weeks. Patient was followed up for one yrs with no evidence of recurrence.

Fig.1[A]. Preoperative photograph showing tongue abscess right dorsum anteriorly.

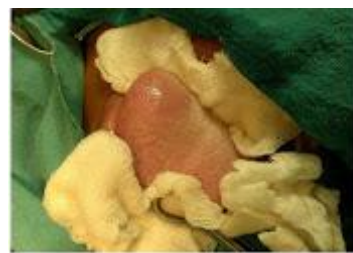

Fig. 1[A]

Fig.1 [B]. FNAC of tongue swelling

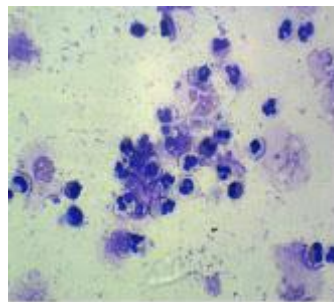


Fig. 1[B]

Fig.1[C]. HPE was showed nonspecific chronic inflammatory granulation tissue between the tongue muscle fascicles.

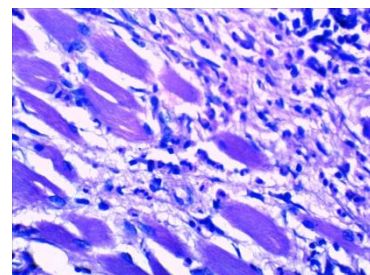


Fig 2[A]. Photograph showing tongue abscess right side anterior two third region

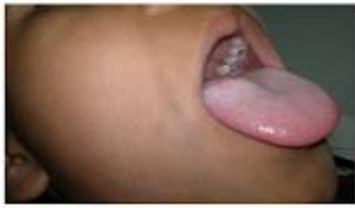

Fig. 2[A]

Fig. 2[B]. USG of tongue showing hypo echoic mass lesion with surrounding oedema.

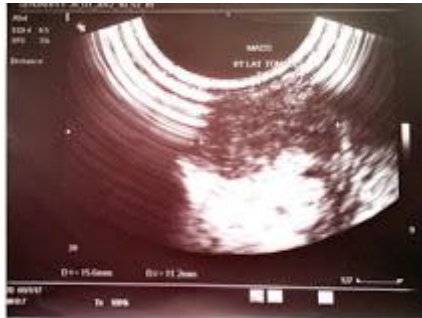

Fig. 2[B]

DISCUSSION

Although the tongue is constantly subjected to trauma, the inflammatory conditions of the tongue resulting from acute trauma are rare. Some of the reasons for this immunity include the constant mobility of the tongue, which helps the saliva produce a perpetual cleansing effect, its thick covering of keratinized mucosa, which is not easily penetrated by micro-organisms, the muscle tissue, which constitutes the chief bulk of its parenchyma, with its rich vascular supply, its rich lymphatic drainage; and the immunologic properties of saliva[6][7]

Epidemiologically is more associated to the male gender, to smoking, to the use of dental prostheses and poor oral hygiene[8]Quite often no specific cause can be identified[9]The aetiology of a tongue abscess may differ depending on its location. The anterior two thirds of the tongue commonly known as “oral tongue” is freely moving part that lies anterior to the circumvallates papillae. Posterior to the circumvallates papillae is the “tongue base” and is regarded as a part of the oropharynx[10]

Glossal abscess is more frequently found on anterior portion of the tongue and is usually unilateral, being related to direct trauma [5] but as in our case there is no history of trauma. In the posterior third of the tongue, the abscess most often originates as lingual tonsillar infection, infected thyroglossal duct cysts, or extensions of apical or periodontal infection from lower molars[7][11]Abscesses located in the mobile tongue are easy to diagnose on the basis of the physical findings. However, those situated in

the base of tongue may pose a diagnostic challenge [12] because the symptoms are less specific and other

inflammatory processes, such as peritonsillitis or infection of the floor of the mouth, may be indistinguishable[13]

The diagnosis must be done by the clinical history, correlating the risks factors associated with smoking, poor oral hygiene, use of dental prostheses and sex, physical exam of the oral cavity and frequently in confirming image exams[14]The symptoms of acute tongue abscess are swelling or a lump in the deep tissue of the tongue, pain radiating toward the ears, throbbing local pain, fever, difficulty in swallowing, voluntary fixation of the tongue because of pain, and, later, difficulty in breathing. Although with the help of these findings, the diagnosis of glossal abscess can be reached clinically, sometimes no specific sign or symptom is present, making diagnosis difficult[6,13].As in our second case only swelling of tongue present, patient was consulted to hospital due to fear of tumour.

The differential diagnosis from the anterior lesions of the tongue includes lingual artery false aneurysm,tuberculosis, syphilis, neoplasms and actinomycosis[4][15][16]

Oral tubercular lesions should particularly beconsidered in the differential diagnosis of tongue abscess,as the tongue being the most common site for oralinvolvement by tuberculosis[5]

The lesions from the posterior third must include thyroglossal cyst and lingual tonsil abscess.[4] Infarctions, edema, macroglossia due to hypopituitarism, metabolic alterations as deficiency of vitamin B12 , hypothyroidism, amyloidosis, acromegaly, iron deficiency, also must be considered as differential diagnosis[3]Several imaging techniques, including sonography, CT, and MR imaging, can be used to evaluate the tongue swellings[6][7][13]The ultrasonography defines and differentiates cystic structures, vascularized and abscesses but in the tongue there is a difficult for the use of the transducer[14]Sonographic depiction of a lingual abscess as a hypoechoic lesion surrounded by a hyperechoic ring has been reported, but sonography is not always feasible because when the tongue is swollen, the patient may experience discomfort or acute pain if it is pressed [6][7]

The computed tomography allows definition and anatomical relation of the lesion mostly in the posterior third of the tongue[14] Needle aspiration of pus collection was a useful diagnostic and therapeutic tool, which provides considerable amelioration of symptoms[13]The same technique was used in our patients also. The diagnosis in our case was basically clinical but imaging and further smears analysis, culture, histopathology confirmed the diagnosis.

Antiseptic mouth washes are indicated until a focus of liquefaction is discernible. Incision on the lateral aspect of the tongue was given in our first case. That was practised and preferable owing to the muscular structure, this permits a more rapid agglutination of the surfaces after the packing is removed; and if any complication, such as haemorrhage, arise, it can more easily be controlled by suture[17]

The antibiotic therapy used in our case, gives adequate coverage for the microorganisms more commonly responsible for the abscess of the tongue. They compose a mixed flora and are frequently present in the superior airway and in the flora of the oral cavity[14]The most common are the Streptococcus viridans, Haemophilus influenzae, Staphylococcus aureus, Bacterioides, Neisseria, and others [6][7][8][15]

Drainage for guided puncture by ultrasonography, being this a less invasive procedure, with lower risks of bleedings also effective in the drainage of the abscess[15]

The good prognosis and the none recurrence of the abscess in cases where are performed abscess drainage (surgical or by puncture) is due to the factors of protection presented by the tongue like the bactericidal action of saliva, its rich vascularisation and the musculature that when contracting limits the inflammation and the cavity formed by the abscess[15]In addition to the general septicemic character of the complication, local dangerous phenomena, which render the prognosis rather bad, should always be borne in mind. Impending suffocation due to the extreme swelling, rupture of the abscess with the opening of a vein and resulting hemorrhage, spread of the infection into the submental connective tissue with a consequent Ludwig's angina, extension to the peritonsillar or post-pharyngeal region, pulmonary or mediastinal structures, are ominous possibilities[17]

CONCLUSION

The tongue abscesses call for prompt clinical diagnosis and aggressive management because they are potentially life-threatening infections. USG is very much useful cheaper investigation helpful both in diagnosis and guided aspiration. Antimicrobial therapy is the cornerstone of treatment, and prompt incision and drainage as indicated. Patient was encouraged for good oral hygiene and also searched for any immune-compromised state.

REFERENCES

- [1] Knight LC. Lingual abscess: a rarity. Br J Clin Pract 1991; 45:294-5.
- [2] Combiere and Murad: Presse med., Sept. 13, 1922.
- [3] Antoniadis K, Hadjipetrou L, Antoniadis V, et al. Acute tongue abscess. Report of three cases. Oral Surg Oral Med Oral Pathol Oral Radiol Endod 2004; 97:570-73.
- [4] Hehar SS, Johnson IJ, Jones NS. Glossal abscess presenting as unilateral tongue swelling. J Laryngol Otol 1996; 110:389-90.
- [5] Byahatti SM, Ingafou MSH. Lingual abscess- a rarity. J Clin Exp Dent 2011;3:162-5.
- [6] Ozturk M, Durak AC, Ozcan N, et al. Abscess of the tongue: findings on MR imaging. AJR Am J Roentgenol 1998; 170:797-98.
- [7] Munoz A, Ballesteros AI, Brandariz Castelo JA. Primary lingual abscess presenting as acute swelling of the tongue obstructing the upper airway: diagnosis with MR. AJNR Am J Neuroradiol 1998; 19:496-98.
- [8] Sands M, Pepe J, Brown RB. Tongue abscess: case report and review. Clin Infect Dis 1993; 16:133-35
- [9] Balatsouras DG, Eliopoulos PN, Kaberos AC. Lingual abscess: diagnosis and treatment. Head Neck 2004; 26:550-5
- [10] Ozturk M, Yorulmaz I, Guney E, et al. Masses of the tongue and floor of the mouth: findings on magnetic resonance imaging. Eur Radiol 2000; 10:1669-74.
- [11] Brook I. Recovery of anaerobic bacteria from a glossal abscess in an adolescent. Pediatr Emerg Care 2002; 18:358-9.
- [12] Ho J, Bush SP. Clinical pearls: painful tongue swelling. Acad Emerg Med 2000; 7:918,941-3.
- [13] Rencham A, Morton M. Acute enlargement of the tongue. Br J Oral Maxillofac Surg 1993;31:321-24.
- [14] Thiago Bittencourt Ottoni de Carvalho, Athlio Maximino Fernandes, Raphael Angelo Sanches. Tongue Abscess: Case Report. Intl. Arch. Otorhinolaryngol 2012; 16 :126-129.
- [15] Kim HJ, Lee BJ, Kim SJ, Shim WY, Baik SK, Sunwoo M. Tongue Abscess Mimicking Neoplasia. Am J Neuroradiol. 2006, 27: 2202-03.
- [16] Zamorro MTL, Pérez ML, Soriano JAM, Sanz GM. Actinomycosis de base de lengua. Acta Otorrinolaringol Esp. 2005, 56:222-225.
- [17] Abraham O. Wilensky, Joseph Harkavy, Abscess of the tongue. Annals of surgery 1923; 78:496-500.