IJMHR
International Journal of Medicine & Health Research
www.internationalmedicalpublishing.com

*Case Report*

**Section: Pathology**

# When a Dermoid Turns Deadly: A Rare Case of Adenocarcinoma Arising in a Mature Cystic Teratoma of the Ovary

**Karishma Dhingra[1*], Neetu Purwar[1], Swapnil Gupta[1], Chayanika Kala[1] & Lubna Khan[1]**

[1]Department of Pathology, Ganesh Shankar Vidyarthi Memorial Medical College, Kanpur, Uttar Pradesh, India

## HIGHLIGHTS

- Rare adenocarcinoma in teratoma
- Malignant transformation in elderly
- Large ovarian mass presentation
- Extensive sampling aids diagnosis
- Exclude extraovarian primary

**Key Words:**
Mature cystic teratoma
Adenocarcinoma
Malignant transformation
Ovary
Case report

## ABSTRACT

**Introduction:** Mature cystic teratoma is a common benign ovarian germ-cell tumour, whereas malignant transformation is rare and occurs predominantly in older women. Squamous cell carcinoma is the most frequent malignancy arising within these tumours, while adenocarcinoma is exceptionally uncommon and may mimic primary ovarian or metastatic gastrointestinal adenocarcinoma. **Aim & Objective:** To describe the clinicopathological features of a rare case of adenocarcinoma arising within an ovarian mature cystic teratoma and to emphasize the importance of thorough histopathological evaluation and exclusion of an extraovarian primary. **Case Presentation:** A 59-year-old woman presenting with a large abdominopelvic mass suspected to be ovarian in origin was evaluated. Ultrasonography, serum CA-125 assessment, surgical excision, and detailed histopathological examination were performed. The resected specimen was extensively sampled, particularly the solid and necrotic areas, to identify malignant transformation and correlate the findings with the mature teratomatous components. **Results:** Ultrasonography revealed a 20.0 × 15.1 cm multiloculated hypoechoic abdominopelvic lesion with mild ascites. Serum CA-125 was approximately 180 U/mL. The patient underwent surgical excision of the ovarian mass with the uterus, cervix, and bilateral adnexa. Histopathological examination demonstrated mature tissues derived from all three germ layers along with malignant glandular proliferation, confirming adenocarcinoma arising within a mature cystic teratoma. **Conclusion:** Adenocarcinoma arising within a mature cystic teratoma represents an exceptionally rare form of somatic malignant transformation. It should be considered particularly in postmenopausal women presenting with large ovarian masses. Thorough sampling and histopathological assessment are essential for diagnosis, while exclusion of an extraovarian primary adenocarcinoma is crucial. Complete excision, appropriate staging, and structured oncological follow-up are important for management and prognostic assessment.

*** Corresponding Author:** Karishma Dhingra, e-mail: priyanshudhingra95@gmail.com
**Article History:** Received 04 August 2026; Received in Revised form 21 September 2026; Accepted 28 September 2026
**How To Cite:** Karishma Dhingra, Neetu Purwar, Swapnil Gupta, Chayanika Kala & Lubna Khan. When a Dermoid Turns Deadly: A Rare Case of Adenocarcinoma Arising in a Mature Cystic Teratoma of the Ovary. *IJMHR: International Journal of Medicine & Health Research.* 2026;14(2):1-6.
DOI: https://doi.org/10.71393/zscfxy28
This publication is licensed under CC-BY 4.0. Copyright © 2026 The Authors. Published by International Medical Publishing Group.

## INTRODUCTION

Mature cystic teratoma of the ovary, commonly known as a dermoid cyst, is the most frequent ovarian germ-cell neoplasm and is usually a benign, slow-growing tumour. It contains mature tissues derived from one or more embryonic germ layers, including skin, hair follicles, sebaceous glands, cartilage, bone, respiratory epithelium, thyroid tissue and gastrointestinal-type mucosa [1]. Although its clinical course is generally favourable, complications such as torsion, rupture, infection and malignant transformation may occur. Malignant transformation is uncommon, with a reported frequency of approximately 0.5% to 3%, and is seen more often in older and postmenopausal women [2]. Squamous cell carcinoma accounts for most malignant transformations, whereas adenocarcinoma represents a distinctly rare histological subtype [3].

Adenocarcinoma may arise from glandular components within the teratoma and can show mucinous, intestinal or other patterns of differentiation. Its diagnosis may be challenging because the morphology can resemble a primary ovarian mucinous carcinoma or metastatic adenocarcinoma from the gastrointestinal tract [4]. Demonstration of malignant glandular proliferation in association with mature teratomatous elements is therefore essential for establishing a teratomatous origin, with immunohistochemistry and clinical evaluation used when required to exclude an extraovarian primary malignancy [5]. **Figure 1:** Dermoid Turns Malignant: Rare Adenocarcinoma in Ovarian Mature Cystic Teratoma.

Preoperative recognition of malignant transformation is difficult because symptoms, imaging findings and tumour-marker abnormalities are often nonspecific. Advanced age, postmenopausal status, rapid enlargement, large tumour size, irregular solid components and elevated serum tumour markers may raise suspicion, but definitive diagnosis generally depends on histopathological examination [6]. Adequate sampling of solid, nodular, haemorrhagic and necrotic areas is particularly important because malignant foci may be limited within an otherwise mature teratoma. Because adenocarcinoma arising in a mature cystic teratoma is exceptionally rare and evidence is largely limited to case reports and small series, reporting such cases remains particularly important for improving clinical recognition, diagnosis and clinicopathological understanding of this unusual malignant transformation [7].

## CASE PRESENTATION

A 59-year-old woman presented with a large abdominopelvic mass suspected to be ovarian in origin. Ultrasonography revealed a large multiloculated hypoechoic lesion measuring approximately 20.0 × 15.1 cm in the lower abdomen and pelvis, with mild ascites; both ovaries were not separately visualized. Serum CA-125 was elevated at approximately 180 U/mL. Cear fluid, hair and necrotic material with multiple loculations, firm areas and a firm-to-hard bony area **(Figure 2)**. After this line to microscopic examination of the ovarian cyst **(Figure 3)**.

The patient underwent surgical excision of the ovarian mass along with removal of the uterus, cervix and bilateral adnexa. The ovarian cyst and the remaining surgical specimens were submitted for gross and microscopic histopathological examination. The uterus with cervix measured 8 × 5 × 4 cm; no remarkable gross findings were noted on cut section, and the bilateral adnexa were largely unremarkable grossly. The ovarian cyst measured 23 × 17 × 10 cm and had a smooth, glistening external surface. On cut section, it contained clear fluid, hair and necrotic material with multiple loculations, firm areas and a firm-to-hard bony area.

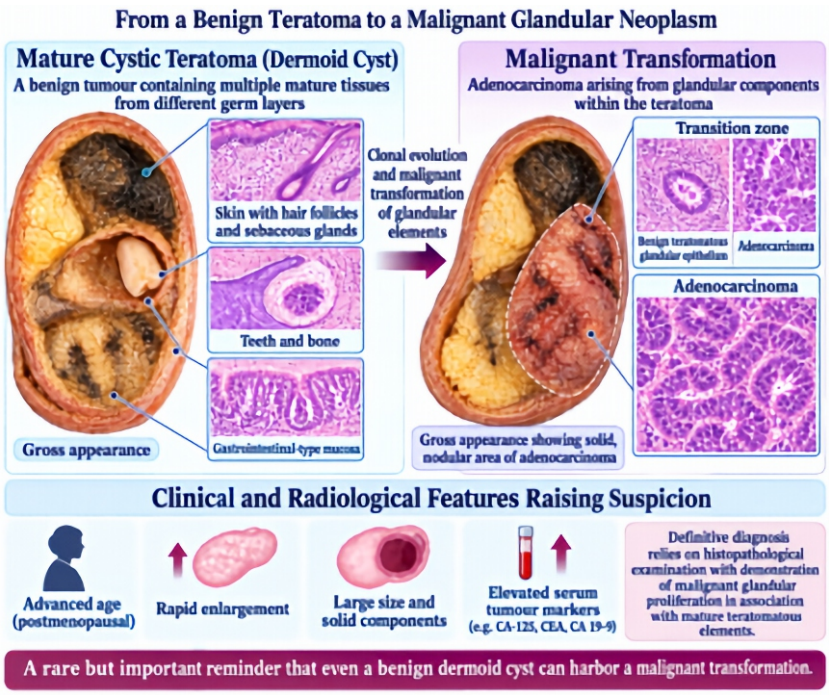


**Figure 1: Rare Adenocarcinoma in Ovarian Mature Cystic Teratoma**

Microscopic examination of the ovarian cyst **(Figure 3)** demonstrated mature derivatives of ectoderm and mesoderm **(Figure 4)** all three germ layers, including keratinizing squamous epithelium with pilosebaceous units, mature adipose and osseous tissue, and glandular elements. Mature and immature derivatives of endoderm **(Figure 5)**. Areas of irregular malignant glandular proliferation were identified, confirming adenocarcinoma arising in a mature cystic teratoma of the ovary **(Figure 6)**. The associated surgical specimens showed no significant abnormal histopathological findings. The final histopathological diagnosis was adenocarcinoma arising in a mature cystic teratoma of the ovary.

## RESULTS

The patient, a 59-year-old woman, presented with a large abdominopelvic mass suspected to be ovarian in origin. Ultrasonography demonstrated a 20.0 × 15.1 cm multiloculated hypoechoic ovarian lesion associated with mild ascites. Serum CA-125 was approximately 180 U/mL. The patient underwent surgical excision of the ovarian mass along with the uterus, cervix, and bilateral adnexa. Gross examination revealed a large cystic ovarian mass measu-ring approximately 23 × 17 × 10 cm, containing characteristic hair, sebaceous material, solid areas, and necrotic foci, suggest-I've of a mature cystic teratoma with malignant transformation. Histopathological examination demonstrated mature tissues derived from all three germ layers, including keratinized squamous epithelium, pilosebaceous structures, adipose tissue, and other mature components. In addition, areas of malignant glandular proliferation were identified within the teratomatous tissue. The malignant component showed features consistent with adenocarcinoma, establishing the diagnosis of adenocarcinoma arising within a mature cystic teratoma of the ovary. The combination of mature teratomatous elements and malignant glandular differentiation supported a teratomatous origin. Extensive sampling of the solid and necrotic areas was particularly important in demonstrating the malignant transformation and excluding the possibility of an occult primary ovarian or extraovarian adenocarcinoma.

**Figure 2. Gross photograph of the opened ovarian cyst showing hair, sebaceous material, necrotic areas and solid tissue, consistent with a mature cystic teratoma with suspected malignant transformation.**

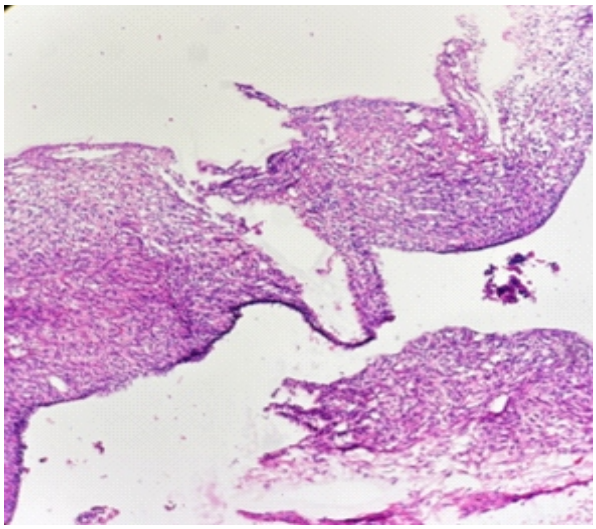

**Figure 3. Low-power photomicrograph showing the wall of the ovarian cyst (H&E, ×10).**

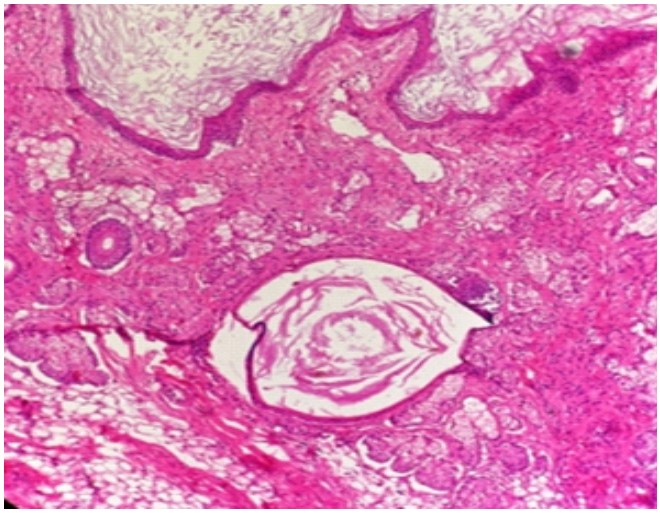

**Figure 4. Low-power photomicrograph showing keratinized stratified squamous epithelium with pilosebaceous units and mature adipose tissue (H&E, ×10).**

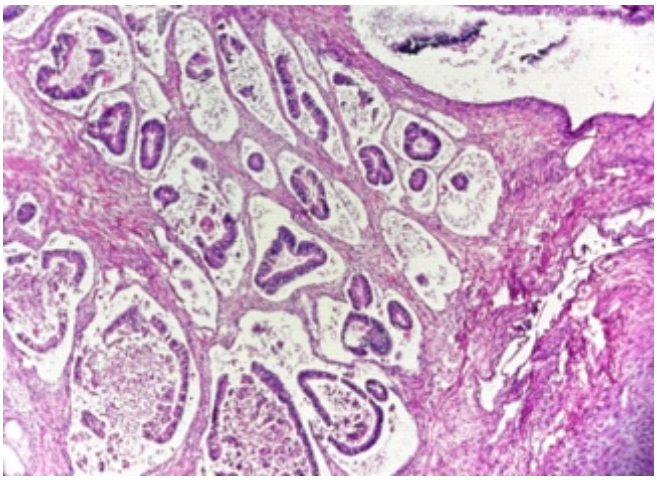

**Figure 5. Low-power photomicrograph showing irregular infiltrating malignant glands invading the ovarian stroma (H&E, ×10).**

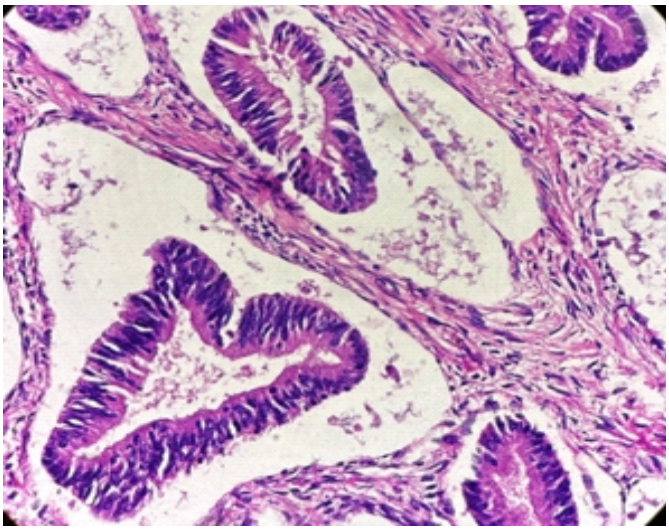

**Figure 6. High-power photomicrograph showing irregular infiltrating malignant glands within the ovarian stroma (H&E, ×40).**

## CONCLUSION

Adenocarcinoma arising in a mature cystic teratoma of the ovary is an exceptionally rare malignant transformation that should be considered in older women presenting with large, complex ovarian masses. In this case, the combination of teratomatous elements from all three germ layers and malignant gland-forming epithelium established the diagnosis. The findings emphasize the importance of thorough gross examination, extensive sampling of solid or necrotic areas, and careful histopathological evaluation. Complete surgical excision, staging, exclusion of an extra-ovarian primary, and structured oncological follow-up are essential because prognosis depends mainly on disease stage, residual tumour, and timely institution of appropriate adjuvant therapy.

## CLINICAL SIGNIFICANCE

The clinical significance of this study lies in its potential to bridge the gap between research findings and practical healthcare applications. It emphasizes the importance of translating scientific observations into meaningful improve-ments in patient care, diagnosis, and treatment outcomes. By highlighting real world relevance, the study contributes to evidence based medical practice and supports informed clinical decision making. Ultimately, the findings aim to enhance patient quality of life, optimize therapeutic strategies, and promote better disease management in clinical settings.

## ABBREVIATIONS

**CA-125**: Cancer Antigen 125
**USG**: Ultrasonography
**SCC**: Squamous Cell Carcinoma
**MCT**: Mature Cystic Teratoma
**GIT**: Gastrointestinal Tract

## AUTHOR INFORMATION

Dr. Karishma Dhingra: Senior Resident,
https://orcid.org/0000-0001-7237-8780
Dr. Neetu Purwar: Assistant Professor,
https://orcid.org/0000-0003-1443-3352
Dr. Swapnil Gupta: Assistant Professor,
https://orcid.org/09-0006-6226-6957
Dr. Chayanika Kala: Associate Professor,
https://orcid.org/0000-0003-1443-3352
Dr. Lubna Khan: Head of Department & Professor,
https://orcid.org/0000-0001-9444-2165

## AUTHOR CONTRIBUTIONS

All authors significantly contributed to the study conception and design, data acquisition, or data analysis and interpretation. They participated in drafting the manuscript or critically revising it for important intellectual content, consented to its submission to the current journal, provided final approval for the version to be published, and accepted responsibility for all aspects of the work. Additionally, all authors meet the authorship criteria outlined by

## ACKNOWLEDGEMENT

The authors sincerely acknowledge the seniors of the Department of Pathology, Ganesh Shankar Vidyarthi Memorial Medical College, Kanpur, Uttar Pradesh, India . We are grateful to our college for providing the necessary resources to carry out this work. We also extend our heartfelt thanks to our colleagues and technical staff for their valuable assistance during the study.

## CONFLICT OF INTEREST

Authors declared that there is no conflict of interest.

## FUNDING

None

## ETHICAL APPROVAL & CONSENT TO PARTICIPATE

All necessary consent & approval was obtained by authors.

## CONSENT FOR PUBLICATION

All necessary consent for publication was obtained by authors.

## DATA AVAILABILITY

All data generated and analyzed are included within this research article. The datasets utilized and/or analyzed in this study can be obtained from the corresponding author upon a reasonable request.

## USE OF ARTIFICIAL INTELLIGENCE (AI) & LARGE LANGUAGE MODEL (LLM)

The authors confirm that no AI & LLM tools were used in the writing or editing of the manuscript, and no images were altered or manipulated using AI & LLM.

## AUTHOR'S NOTE

This article serves as an important educational tool for the scientific community, offering insights that may inspire future research directions. However, they should not be relied upon independently when making treatment decisions or developing public health policies.

## PUBLISHER'S NOTE

All statements made in this article are the sole responsibility of the authors and do not necessarily reflect the views of the publisher, editors, or reviewers. The journal maintains a neutral stance regarding jurisdictional claims in institutional affiliations presented in published work.

## ARCHIVING INFORMATION

- zenodo
- Self-archiving on Google and Amazon Web Services (AWS) cloud servers, as well as on three dedicated in-house servers
- PKP Preservation Network

**MANAGING & PUBLISHING EDITOR**
**Dr. Vinay Kumar Yadav**[1,2,3]
[1]CSIR-Indian Institute of Toxicology Research (IITR), Lucknow, India
[2]Academy of Scientific and Innovative Research (AcSIR), Ghaziabad, U.P., India
[3]Biological E Ltd, Hyderabad, Telangana, India

**HANDLING EDITOR**
**Dr. Karan Singh Saini**[1,2,3]
[1]Ph.D. in Cancer Research from CDRI-JNU New Delhi, India & [2]Post-Doctoral Fellow from University of Illinois at Chicago, USA
[3]Department of Zoology, P.M. College of Excellence, Government Postgraduate College in Sheopur, Madhya Pradesh, India

## REFERENCES

1. Goudeli C, Varytimiadi A, Koufopoulos N, Syrios J, Terzakis E. An ovarian mature cystic teratoma evolving in squamous cell carcinoma: a case report and review of the literature. Gynecol Oncol Rep. 2017;19:27-30. https://doi.org/10.1016/j.gore.2016.12.005
2. Cong L, Wang S, Yeung SY, Lee JHS, Chung JPW, Chan DYL. Mature cystic teratoma: an integrated review. Int J Mol Sci. 2023;24(7):1-13.
3. Atwi D, Kamal M, Quinton M, Hassell LA. Malignant transformation of mature cystic teratoma of the ovary. J Obstet Gynaecol Res. 2022;48(12):3068-3076. https://doi.org/10.1111/jog.15409
4. Belaid I, Khechine W, Ben Abdelkader A, Bedioui A, Ezzairi F, Chabchoub I, et al. Adenocarcinoma of intestinal type arising in mature cystic teratoma of ovary: a diagnostic dilemma. Clin Case Rep. 2020;8(4):644-647. https://doi.org/10.1002/ccr3.2718
5. Vang R, Gown AM, Zhao C, Barry TS, Isacson C, Richardson MS, et al. Ovarian mucinous tumors associated with mature cystic teratomas: morphologic and immunohistochemical analysis identifies a subset of potential teratomatous origin that shares features of lower gastrointestinal tract mucinous tumors more commonly encountered as secondary tumors in the ovary. Am J Surg Pathol. 2007;31(6):854-869. https://doi.org/10.1097/pas.0b013e31802efb45
6. Park CH, Jung MH, Ji YI. Risk factors for malignant transformation of mature cystic teratoma. Obstet Gynecol Sci. 2015;58(6):475-480. https://doi.org/10.5468/ogs.2015.58.6.475
7. Miyasaka A, Nishikawa T, Kozawa E, Yasuda M, Fujiwara K, Hasegawa K. Advanced mucinous adenocarcinoma arising from a mature cystic teratoma: a case report and literature review. Case Rep Oncol. 2016;9(2):331-337. https://doi.org/10.1159/000447258
8. Li Y, Qin M, Shan Y, Wu HW, Liu XD, Yin J, et al. 30-year experience with 22 cases of malignant transformation arising from ovarian mature cystic teratoma: a rare disease. Front Oncol. 2022;12:1-10. https://doi.org/10.3389/fonc.2022.842703
9. Clark ME, Will MD. Intestinal-type adenocarcinoma arising in a mature cystic teratoma of the ovary. Int J Gynecol Pathol. 2016;35(4):352-356. https://doi.org/10.1097/pgp.0000000000000258
10. Min KJ, Jee BC, Lee HS, Kim YB. Intestinal adenocarcinoma arising in a mature cystic teratoma of the ovary: a case report. Pathol Res Pract. 2006;202(7):531-535. https://doi.org/10.1016/j.prp.2006.03.005
11. Hershkovitz D, Vlodavsky E, Simon E, Ben-Izhak O. KRAS mutation positive mucinous adenocarcinoma originating in mature ovarian teratoma: case report and review of literature. Pathol Int. 2013;63(12):611-614. https://doi.org/10.1111/pin.12123
12. Snir OL, Buza N, Hui P. Mucinous epithelial tumours arising from ovarian mature teratomas: a tissue genotyping study. Histopathology. 2016;69(3):383-392. https://doi.org/10.1111/his.12959

**Cite this article :** Karishma Dhingra, Neetu Purwar, Swapnil Gupta, Chayanika Kala & Lubna Khan. When a Dermoid Turns Deadly: A Rare Case of Adenocarcinoma Arising in a Mature Cystic Teratoma of the Ovary. *IJMHR: International Journal of Medicine & Health Research.* 2026;14(2):1-6.