

BMR Medicine

Research Article

Study of Lichen Planus and its different types and associated conditions

Shankar Gouda Ireddy¹ and Sudheendra G Udbalkar²

¹Department of Skin & VD, Raichur Institute of Medical Sciences, Raichur, Karnataka, India

²Consulting Dermatologist, Fortis Hospital, Bengaluru, Karnataka, India

Correspondence should be addressed to **Shankar Gouda Ireddy**

Received 26 July 2014; Accepted 30 July 2014; Published 1 August 2014

Copyright: © 2014 **Shankar Gouda Ireddy** et al. This is an open access article distributed under the Creative Commons Attribution License, which permits unrestricted use, distribution, and reproduction in any medium, provided the original work is properly cited.

Abstract

Lichen planus is associated with significant morbidity because of the severe itching that most of the patients suffer from and also due to post-inflammatory pigmentation seen at the site of lesions that is quite resistant to treatment. Even though lichen planus has been described as self-limiting disease, it has been shown that the recurrences in the disease are quite common. Another cause of concern is the development of squamous cell carcinoma in few cases of oral lichen planus and hypertrophic lichen planus.

Objectives of the study are;

1. To study different clinical types of lichen planus.
2. To study association of lichen planus with other diseases
3. To study histological features in different clinical types of lichen planus

After taking history, a thorough general physical examination was done to look for any other associated abnormalities. Systemic examination was done in all cases to look for any systemic abnormalities which were noted. Cutaneous examination was done with regard to the morphology of the lesions, configuration of the lesions, distribution of the lesions, presence or absence of Koebner's phenomenon. Oral mucosa, genital mucous membrane & nails were examined to look for any associated lesions. In our study no association of lichen planus was seen with hepatitis C, hepatitis B and liver abnormalities. Diabetes mellitus and hypertension were common associated systemic disease, while alopecia areata and vitiligo were associated cutaneous disorders.

Keywords: Lichen planus, Histology, Associated diseases

Introduction

Lichen planus presents with different type of clinical lesions and with different configurations resulting in several clinical types. Lichen planus not only occurs on skin but can also affect various mucous membranes like oral, vaginal, pharynx, larynx, esophagus, conjunctiva and lacrimal duct etc causing significant discomfort. Lichen planus can also involve hair follicle leading to scarring alopecia. Lichen planus can involve nails causing significant damage to nail matrix resulting in various abnormalities of nail. Lichen planus lesions can show Koebner's phenomenon with development new lesions at sites of trauma in the uninvolved skin.

Lichen planus is associated with significant morbidity because of the severe itching that most of the patients suffer from and also due to post-inflammatory pigmentation seen at the site of lesions that is quite resistant to treatment.

Even though lichen planus has been described as self-limiting disease, it has been shown that the recurrences in the disease are quite common. Another cause of concern is the development of squamous cell carcinoma in few cases of oral lichen planus and hypertrophic lichen planus.

Lichen planus can be confidently diagnosed on clinical grounds but in some cases it has to be differentiated from lichenoid eruptions. Lichenoid eruptions show histological picture similar to lichen planus but with some subtle changes that help in differentiating it from lichen planus. Lichenoid eruptions can occur as a reaction to several drugs such as ACE-inhibitors, calcium channel blockers, beta blockers, Gold salts, thiazide diuretics, furosemide, spironolactone, pencillamine etc.

Histologically lichen planus is classically characterized by interface dermatitis with shows basal cell vacuolation, band-like lymphocytic infiltrate in the upper dermis hugging onto the dermo-epidermal junction.

Lichen planus is treated with several treatment modalities like corticosteroids – both oral & topical,

retinoids, immunomodulators and several miscellaneous drugs like dapsone, griseofulvin etc. Treatment of lichen planus in some cases is unsatisfactory. Until etiopathogenesis of lichen planus is better understood treatment is likely to remain unsatisfactory.

Aims & Objective

1. To study different clinical types of lichen planus.
2. To study association of lichen planus with other diseases.
3. To study histological features in different clinical types of lichen planus

Material and Methods

The study was conducted in the out patient department of Dermatology and Venereology at Image hospitals, Ameerpet, Hyderabad on patients with lichen planus. The duration of the study period was from March 2007 to February 2008. A prospective study was conducted over a period of 1 year with all the new patients with a clinical diagnosis of lichen planus being included in the study. Following inclusion and exclusion criteria were used

Inclusion criteria

1. New patients of all age groups and both sex with a clinical diagnosis of lichen planus
2. Patients with all clinical types of lichen planus

Exclusion criteria

1. Old patients of lichen planus on follow-up

Observations

Clinical Type of Lichen Planus

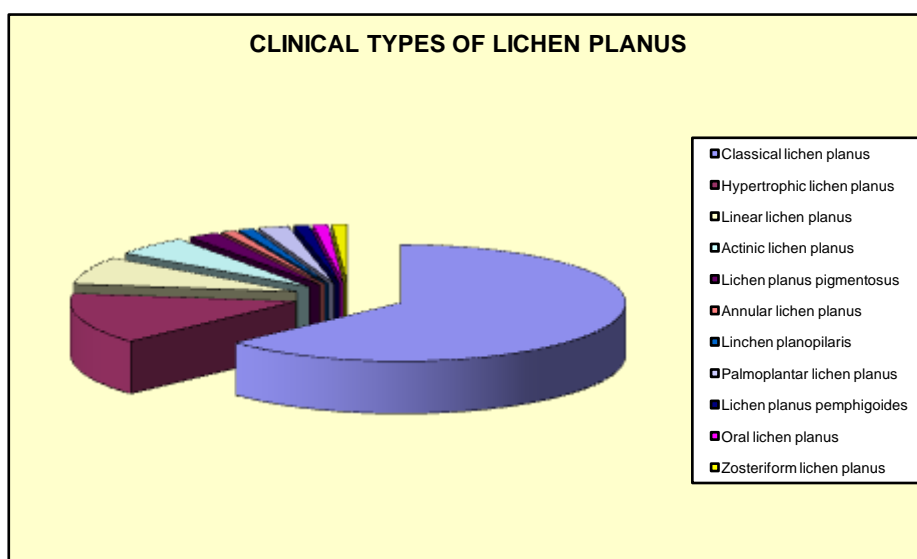
In our study, several clinical types of lichen planus were seen depending on the morphology, configuration & distribution of lesions.

The most common type of lichen planus was classical lichen planus which was seen in 58 (63.04%) patients with 34 being females & 24 being

males. Next most common clinical type was hypertrophic lichen planus that was seen in 13 (14.13%) patients with 6 being female and 7 being males. Third most common clinical type was linear lichen planus that was seen in 7 (7.61%) patients with 5 of them being female and 2 being males. Next common type was actinic lichen planus that was seen in 5 (5.43%) cases out of which 4 were females & 1 was male. Lichen planus pigmentosus was seen in 2 (2.17%) female patients. 2 (2.17%) cases had

plamoplantar lichen planus. 1 (1.09%) case each had annular lichen planus, lichen planopilaris, lichen planus pemphigoides, oral lichen planus & zosteriform lichen planus.

So, the most common type of lichen planus seen in our study was classical lichen planus followed by hypertrophic lichen planus and then linear lichen planus and then actinic lichen planus. Cases of lichen planopilaris, lichen planus pemphigoides were seen less commonly.



In our study the type of lichen planus was correlated with duration of disease, it was found that 0 to 3 months was the most common duration of disease. Most of the cases of hypertrophic lichen planus had duration of disease in 10 to 12 months range. So, the duration of disease was higher in hypertrophic lichen planus.

When age distribution of the different clinical variants of lichen planus was studied it was found that, classical lichen planus was seen most commonly in the age group of 20 to 39 years, while hypertrophic and linear lichen planus were seen most commonly in the age group of 40 to 59 years.

Koebner's Phenomenon

Koebner's phenomenon i.e the occurrence of new lesions along the sites of trauma in an unaffected skin was seen 28 (30.43%) patients in this study out of which 19 were females & 9 were males. All

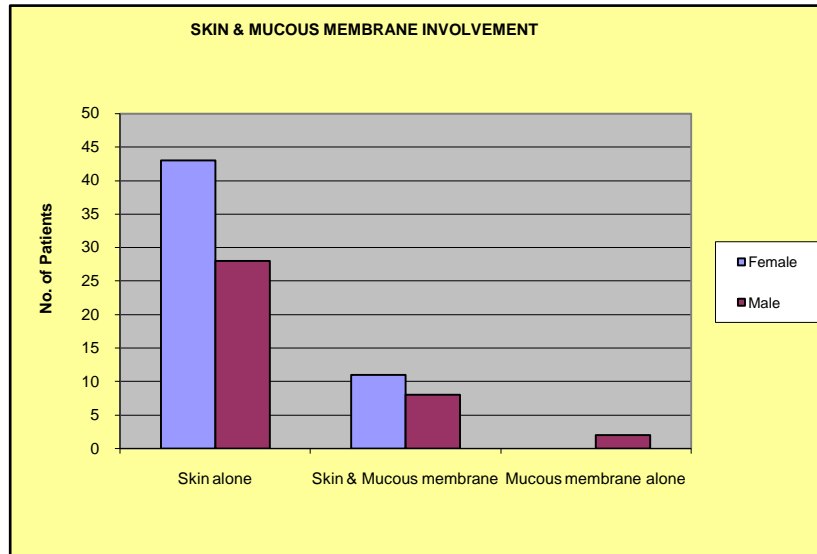
the patients who had Koebner's phenomenon complained of itching.

So Koebner's phenomenon was seen more commonly in patients who complained of itching.

Involvement of Skin & Mucous Membranes

In our study, involvement of skin alone was seen in 71 (77.17%) patients out of whom 43 were females & 28 were males. Involvement of both skin & mucous membranes was seen in 19 patients (20.65%) out of which 11 were females & 8 were males. 2 male patients had involvement of mucous membranes alone, among them 1 had oral lichen planus & another patient had annular lichen planus on glans penis.

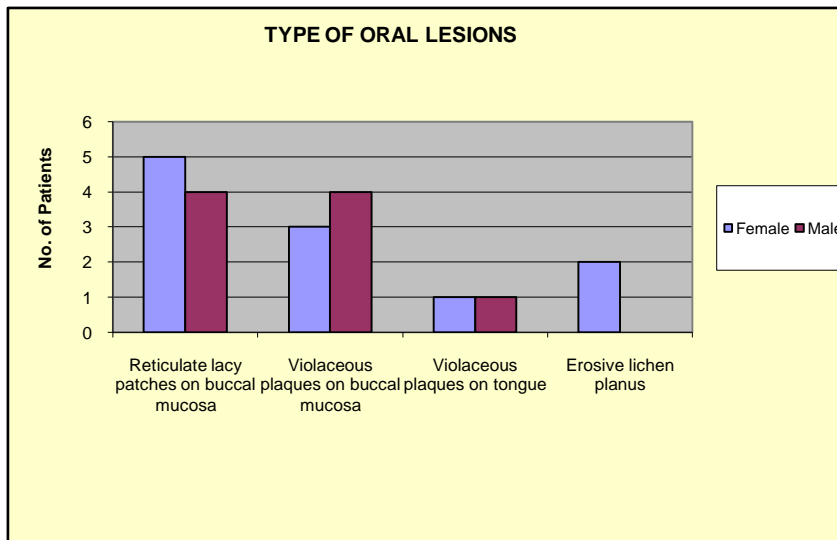
In our study we found that mucous membrane lesions were seen in 22.83% of patients having cutaneous lichen planus.



Oral Involvement

Out of 92 patients, oral mucosal involvement was seen in 20 (21.75%) patients out of whom 11 were females & 9 were males. The oral involvement was seen in the form of reticulate lacy patches on buccal mucosa were seen in 9 (9.78%) patients out of

which 5 were females & 4 were males. 7 (7.61%) patients had violaceous plaques on buccal mucosa & 2 (2.17%) patients had violaceous plaques on tongue. Erosive lichen planus was seen in 2 (2.17%) female patients. 1 male patient had involvement of glans penis. 1 patient with oral lichen planus had a dental amalgam opposite to the site of lesion.

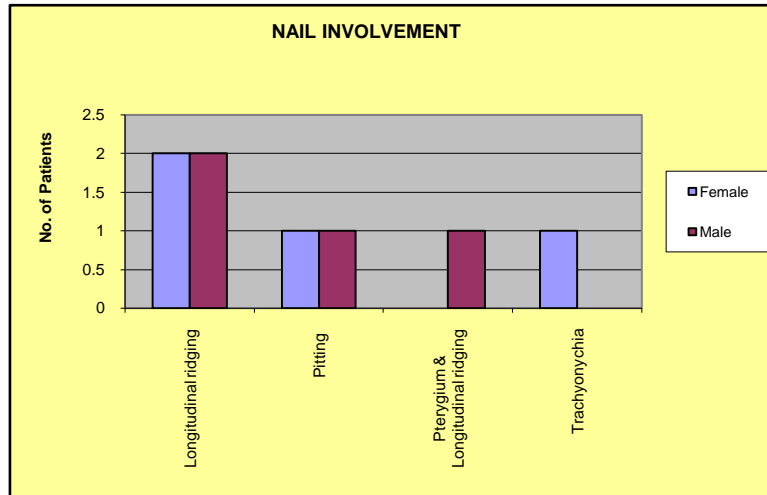


In our study buccal mucosa was the commonest site of involvement with reticular type being the commonest type of oral lichen planus.

Nail Involvement

In our study, nail involvement was seen in 8 (8.69%) out of which 4 were female and 4 were males. Involved nails showed longitudinal ridging in 4 (4.35%) patients with 2 being female & 2 being

males. Pitting of nails was seen in 2 (2.17%) patients with 1 being female & 1 being male. Pterygium of nail & longitudinal ridging was seen in 1 (1.09%) male patient. Trachyonychia was seen in 1 (1.09%) female patient.



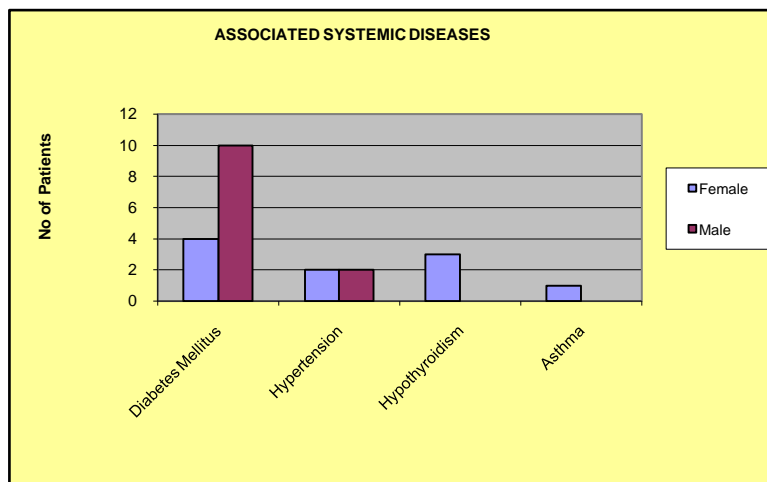
In our study, longitudinal ridging was the commonest nail manifestation. 1 Patient had pterygium & another had twenty nail dystrophy.

Hair Involvement

In our study we found, hair involvement in 5 (5.43%) cases. 3 patients had non-scarring alopecia on scalp with 2 being females & 1 being male. 2 male patients had scarring alopecia on scalp. patients with non-scarring alopecia were having alopecia areata, while one patient with scarring alopecia had pseudopelade of Brocq.

Associated Systemic Diseases

In our study, diabetes mellitus was seen in 14 (15.22%) patients out of whom 4 were females & 10 were males. Hypertension was seen in 4 (4.34%) patients of whom 2 were females & 2 were males. Hypothyroidism was seen in 3 (3.26%) female patients. Asthma was seen in 1 (1.09%) female patient. Few of the patients had diabetes mellitus with hypertension.



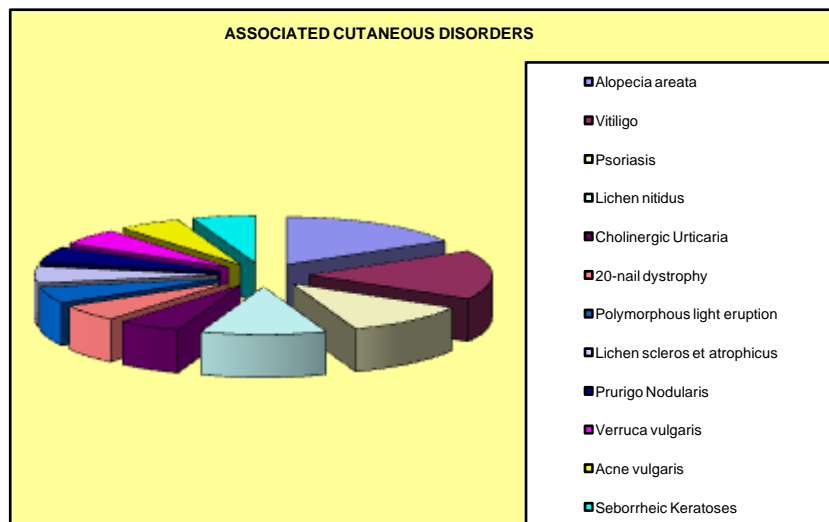
In our study, commonest systemic disease found was diabetes mellitus. In most of the patients with diabetes mellitus, diabetes was diagnosed after lichen planus and they were taking oral hypoglycaemic agents. Patients with hypertension were not taking ACE-inhibitors and Beta-blockers.

Associated Cutaneous Disorders

Associated cutaneous disorders were seen in 18 (19.57%) out of 92 patients out of which 10 were females & 8 were males. Commonest cutaneous disorder seen was alopecia areata & vitiligo seen in 3 patients each. 2 male patients had psoriasis. 2 female patients had lichen nitidus. 1 patient each

had polymorphic light eruption, lichen sclerosus et atrophicus, 20-nail dystrophy, prurigo nodularis, cholinergic urticaria, acne vulgaris, verruca vulgaris, seborrheic keratoses. Associated cutaneous disorders like prurigo nodularis, lichen sclerosus et atrophic, lichen nitidus were confirmed by histopathology.

In our study the most common associated cutaneous diseases seen were alopecia areata and vitiligo.



Histopathology Features

Out of 92 patients, 25 were subjected for biopsies. The histopathology was studied with reference to hyperkeratosis, focal hypergranulosis, acanthosis, saw toothing, basal cell liquefaction, melanin incontinence, civatte bodies.

Basal cell liquefactive degeneration was seen in 25 (100%) cases. Hyperkeratosis was seen in 23 (92%) cases. Focal hypergranulosis was seen in 21 (84%) cases. Acanthosis was seen in 23 (92%). Saw-toothing of rete ridges was seen in 21 (84%). Band like infiltrate of lymphocytes & macrophages was seen in 24 (96%). Melanin incontinence was

seen in 19 (76%). Civatte bodies were seen in 10 (40%). In one patient with lichen planus pemphigoides, the biopsy was also sent for direct immunofluorescence that showed linear deposition of IgG & C3 at the basement membrane zone, thus confirming the diagnosis.

So, the commonest findings seen were basal cell liquefactive degeneration and band-like lymphocytic infiltrate. Cases of actinic lichen planus showed epidermal thinning and didn't have much acanthosis. Hyperkeratosis was prominent in cases of hypertrophic lichen planus. One case of lichen planopilaris showed perifollicular inflammation with degeneration of follicular epithelial cells.

TABLE 1: HISTOPATHOLOGICAL FEATURES IN DIFFERENT CLINICAL TYPES

Clinical Diagnosis	No of Biopsies done	Hyperkeratosis	Focal hypergranulosis	Acanthosis	Saw toothing of rete ridges	Basal cell liquefaction	Band-like inflammatory infiltrate	Melanin incontinence	Civvate Bodies	Any other findings
Classic lichen planus	8	8	6	8	8	8	8	8	4	
Hypertrophic lichen planus	4	4	4	4	4	4	4	3	1	
Actinic lichen planus	2	2	2	0	1	2	2	2	1	
Lichen planus pigmentosus	2	1	2	2	1	2	2	2	1	
Linear lichen planus	3	3	3	3	3	3	3	2	1	
Palmoplantar lichen planus	2	2	2	2	1	2	2	1	1	
Lichen planopilaris	1	1	0	1	0	1	0	0	0	
Oral lichen planus	1	0	0	1	1	1	1	0	1	
Zosteriform lichen planus	1	1	1	1	1	1	1	1	0	
Lichen planus pemphigoides	1	1	1	1	1	1	1	0	0	
Total	24	23	21	23	21	25	24	19	10	
Percent	100%	92%	84%	92%	84%	100%	96%	76%	40%	

Discussion

Clinical Types of Lichen Planus

In our study, most common type of lichen planus was classical lichen planus which was seen in 63.04% followed by hypertrophic lichen planus seen in 14.13% cases, linear lichen planus seen in

7.61% cases, actinic lichen planus seen in 5.43% cases, lichen planus pigmentosus & palmoplantar lichen planus was seen in 2.17%. Lichen planopilaris, lichen planus pemphigoides, oral lichen planus & zosteriform lichen planus were seen in 1.09% case. Our findings were in correlation with the different studies that showed figures as mentioned the table below.

TABLE 2: COMPARISON OF CLINICAL TYPE OF LICHEN PLANUS IN VARIOUS STUDIES

Type of Lichen planus	Present study	O P Singh et al ¹	Kacchawa Dilip et al ²	Salah A Abdallat et al ³	Garg Vijay Kumar et al ⁴	Vijayasingam et al ⁵	Tag-El-Din Anbar et al ⁶
Classic lichen planus	63.04%	74.61%	52	57.7	73.3	64	30
Hypertrophic lichen planus	14.13%	12.70%	1.87	17.8	17.3	11	12
Linear lichen planus	7.61%	--	2.4	--	--	--	--
Actinic lichen planus	5.43%	--	14.13	--	4	--	36
Lichen planus pigmentosus	2.17%	--	6.52	--	--	--	--
Annular lichen planus	1.09%	--	0.27	--	--	--	--
Linchen planopilaris	1.09%	1.81	2.67	1.2	2.7	--	4
Palmoplantar Lichen planus	2.17%	--	0.8	--	--	--	--
Lichen planus pemphigoides	1.09%	1.59	--	--	--	--	--
Oral lichen planus	1.09%	4.76	--	13.77	2.7	17	8
Zosteriform lichen planus	1.09%	--	--	--	--	--	--

Classical lichen planus was the commonest type in all the studies except Tag-El-Din Anbar et al,⁶ who found actinic type of lichen planus was most common type.

Classical lichen planus was the most common type found in our study with 20 to 59 year being common age group. The lesions in these cases were generalized in distribution with lesions predominantly on extremities.

Hypertrophic lichen planus was the second common type found in 14.13% cases, cases of hypertrophic lichen planus had longer duration of disease. Similar finding has been reported by O P Singh et al.¹ It was common in the age group of 40 to 59 years, this correlates with Kacchawa Dilip et al.²

Linear lichen planus was the next most common form found in 7.61% cases. Some studies have found linear lichen planus to be common in childhood, while some studies have found it to be more common among adults.⁷ In our study most of the cases were seen in 40 to 59 years age group.

Actinic lichen planus was seen in 5.43% cases, the lesions in this type were predominantly distributed on sun-exposed areas like forearms, face & V-neck. Some of these patients complained of burning sensation. Similar findings were found by O P Singh et al¹ in there study.

Lichen planus pigmentosus was seen in 2.17% cases with both of them being females. In these cases lesions were predominantly seen on upper limbs, trunk & face. Palmoplantar LP was also seen in 2.17%.

Lichen planus pemphigoides was seen in 1.09% cases, this patient developed multiple vesiculo-bullous lesions on lichen planus lesions & normal skin all over the body. This patient had an acute onset of disease. Similar findings were found in study O P Singh et al.¹ In present study we didn't find any case of atrophic lichen planus that has been reported in other studies.

Koebner's Phenomenon

In present study Koebner's phenomenon was seen in 30.43% cases. Most of the cases that had Koebner's phenomenon complained of itching that was quite severe. Sanjeev Handa et al.¹³ in study of childhood lichen planus found Koebner's phenomenon in 26.5% cases.

Involvement of Skin & Mucous Membranes

In our study, 77.17% cases had lesions only on skin, 20.65% cases had lesions on skin & mucous membranes & 2.17% had lesions only on mucous membranes. Our findings correlate with the figures found in studies mentioned in table below.

Our study findings of skin involvement correlated with other studies. But, lower incidence of isolated mucosal membrane in our study may be because cases of oral lichen planus may be because patients of oral lichen planus are seen by dentists.

In our study oral mucosa involvement was seen in 21.74% cases with reticular involvement of buccal mucosa being the most common presentation. O P Singh et al.¹ & Tag-El-Din Anbar et al.⁶ found oral involvement in 27.21% & 22% cases with reticulate pattern being the common presentation. Oral involvement in lichen planus is seen frequently and reticular form is the common type of lesion.

Nail Involvement

In our study, nail involvement was seen in 8.69% of cases. Longitudinal ridging was the commonest finding seen in 4.34% cases. Our findings correlate with Salah A Abdallat et al.³ who found nail involvement in 9% cases with longitudinal ridging

being the commonest finding. Garg Vijay Kumar et al found nail involvement in 9.33% cases.

Kacchawa Dilip et al.² found nail involvement in 6.4% cases while O P Singh et al.¹ found it only in 1.6% cases, V N Sehgal & Rege et al.⁸ didn't find any nail involvement in their study. Bhattacharya et al.⁹ found it in 15.1% cases. Vijayasingam et al.⁵ found nail involvement in 3% cases. Tag-El-Din Anbar et al.⁶ found it in 18% cases.

One of our cases had twenty nail dystrophy. Nail biopsy was not done for this patient. There have been several reports of twenty nail dystrophy associated with lichen planus.¹⁰

Hair Involvement

In our study we found that 5 (5.43%) cases had hair involvement on scalp, with 3.26% cases having non-scarring alopecia due to alopecia areata & 2.17% cases having scarring alopecia. Our findings correlate with Tag-El-Din Anbar et al.⁶ who found cicatricial alopecia in 4% of their cases, Salah A Abdallat et al.³ found hair involvement in 1.2% cases. One case of scarring alopecia developed pseudopelade of Brocq.

Association of Lichen Planus With Systemic Diseases

In our study, diabetes mellitus was seen in 15.23% cases. In most of the patients diabetes mellitus had an onset after the onset of lichen planus.

Seyhan M et al.¹¹ found 26.7% cases of lichen planus were diabetics. Nigam et al.¹² found abnormalities of oral glucose tolerance test of the nature of type II diabetes mellitus in 30.3% cases of lichen planus. Y. Gül Denli et al.¹³ found diabetes in 15.7% cases of lichen planus. The association has not been proven conclusively. There is need for further study to establish the validity of this association.

In our study, we found hypertension in 4.34% cases. Kacchawa Dilip et al.² found hypertension among 2.4% of cases. We also found 3.26% of cases to have hypothyroidism, 1.09% patient had asthma. Many studies have found association of liver

diseases with lichen planus, in our study we didn't find any associated liver disease or any abnormalities in liver function test. No association was seen with hepatitis C and hepatitis B virus.

There have been several systemic diseases described in association with lichen planus. There is need for further study to understand the association and its importance in etiopathogenesis of lichen planus.

Associated Cutaneous Diseases

In our study, 3.26% cases had associated alopecia areata, 3.26% cases had vitiligo, 2.17% cases had psoriasis, lichen nitidus was seen in 2.17% cases. Other disorders like acne vulgaris, verruca vulgaris, cholinergic urticaria, polymorphic light eruption, seborrheic keratoses were found in 1.09% case each.

Dhar S et al¹⁴ & GISED¹⁵ found association of lichen planus with alopecia areata. Similarly Ahmad K et al¹⁶, Jaswal R et al¹⁷ have found colocalization of vitiligo & lichen planus.

Association lichen planus & psoriasis has been reported rarely. We found 2.17% cases were having psoriasis. Shiohara T et al reported co-existence of lichen planus & psoriasis.¹⁸

Co-existence of lichen planus, alopecia areata & vitiligo may be expected as all of them are T-cell mediated inflammatory diseases. Further studies are required to establish this association & may help in understanding pathogenesis of this condition better.

Histopathological Features

In our study biopsy was done in 25 cases of different clinical types the findings found were analysed. 100% cases showed basal cell liquefaction, 92% showed hyperkeratosis, 92% showed acanthosis, 84% showed focal hypergranulosis, 84% showed saw-toothing of rete ridges, 96% cases showed band-like inflammatory infiltrate, 76% cases showed melanin incontinence & 40% cases showed Civatte bodies. In case of

lichen planus pemphigoides direct immunofluorescence was done it showed linear deposition of IgG & C3 at basement membrane zone.

Our findings correlated with Garg Vijay Kumar et al⁴ study who found hyperkeratosis (100%), focal hypergranulosis (85%), and acanthosis (93%) with toothing of rete ridges (82%) and basal cell liquefaction (100%), a band-like inflammatory infiltrate (100%), melanin incontinence (100%) & Civatte bodies in 37% cases.

Marked hyperkeratosis was found in cases of hypertrophic lichen planus this was also found in study by Garg Vijay Kumar et al.⁴ Cases of actinic lichen planus didn't show acanthosis & epidermal thinning was observed, this was also found by Garg Vijay Kumar et al.⁴

Conclusion

- Classical lichen planus is the most common clinical variant of lichen planus, followed by hypertrophic lichen planus and linear lichen planus. Hypertrophic lichen planus was associated with longer duration of disease and severe pruritus.
- In our study no association of lichen planus was seen with hepatitis C, hepatitis B and liver abnormalities. Diabetes mellitus and hypertension were common associated systemic disease, while alopecia areata and vitiligo were associated cutaneous disorders.
- Histopathological features showed predominantly basal cell degeneration, band-like lymphocytic infiltrate hugging onto dermo-epidermal junction, hyperkeratosis. Cases of hypertrophic lichen planus showed marked hyperkeratosis and actinic lichen planus showed thinning of epidermis.

References

1. Singh OP, Kanwar AJ. Lichen planus in India: an appraisal of 441 cases. *Int J Dermatol* 1976;15:752

2. Kachhawa D, Kachhawa V, Kalla G, Gupta L. A clinico-aetiological profile of 375 cases of lichen planus. *Indian J Dermatol Venereol Leprol* 1995; 61: 276-9.
3. Salah A, Abdalla1, Taghreed J, Maaita. Epidemiological and clinical features of lichen planus in Jordanian patients. *Pak J Med Sci* January - March 2007; 23 (1): 92-94.
4. Garg Vijay Kumar, Nangia Anitha, Logani Kul Bhushan, Sharma Ravi C. Lichen Planus-a Clinico-histopathological. *Ind J Dermatol, Veneol and Lepr*, Year 2000, Volume 66(4): 193-5
5. Vijayasingam SM, Lim KB, Yeoh KH, Cheong WL, Chong YY, Daniel M, Lim HM. Lichen planus: a study of 72 cases in Singapore. *Ann Acad Med Singapore*. 1988 Oct; 17(4):541-4.
6. Tag-El -Din Anbar, Manal Barakat, and Sahar FG. A clinical and epidemiological study of lichen planus among Egyptians of AL-Minya province *Dermatology Online Journal* 11 (2):
7. Sanjeev Handa, and Bijaylaxmi Sahoo, Childhood lichen planus: a study of 87 cases; *Intl J of Dermatol* 2002, 41, 423-427.
8. Sehgal VN, Rege VL. Lichen planus: an appraisal of 147 cases. *Ind J Dermatol Venereol* 1974; 40: 104.
9. Bhattacharya M, Kaur I, Kumar B. Lichen Planus. A Clinical and Epidemiological Study, *J Dermatol* 2000, **VOL.27; 9**;.576-582.
10. Robert A. Silverman, Arthur R. Rhodes. Twenty-Nail Dystrophy of Childhood: A Sign of Localized Lichen Planus. *Pediatric Dermatology* 1984; 1 (3): 207-210.
11. Seyhan M, Ozcan H, Sahin I, Bayram N, Karıncaoglu Y. High prevalence of glucose metabolism disturbance in patients with lichen planus. *Diabetes Res Clin Pract* 2007; 77(2):198-202.
12. Nigam KP, Singh G, Sharma L, Agrawal JK. A correlative study of serum immunoglobulins and glucose tolerance in lichen planus. *Indian J Dermatol Venereol Leprol* 1990; 56: 278-80.
13. Y. Gül Denli, Murat Durdu and Mehmet Karakas. Diabetes and Hepatitis Frequency in 140 Lichen Planus Cases in Çukurova Region. *J Dermatol* 2004; 31 (4): 293-298.
14. Dhar S, Dhar S. Colocalization of alopecia areata and lichen planus. *Pediatr Dermatol*. 1996 May-Jun; 13(3):258-9.
15. Gruppo Italiano Studi Epidemiologici in Dermatologia(GISED). Epidemiological evidence of the association between lichen planus and two immune-related diseases: alopecia and ulcerative colitis. *Arch Dermatol* 1992; 127: 688-91.
16. Ahmad K, Kachhawa D, Khullar R, Khar. Coexistent vitiligo and actinic lichen planus. *Indian J Dermatol Venereol Leprol* 1992; 58:128-30.
17. Jaswal R, Mehta SD, Bedi GK, Kanwar AJ. Coincidence of vitiligo and lichen planus. *Indian J Dermatol Venereol Leprol* 1997; 63: 248-9.
18. Shiohara T, Hayakawa J, Nagashima M. Psoriasis and lichen planus: coexistence in a single patient. Are both diseases mutually exclusive? *Dermatologica*. 1989; 179(4): 178-82.