

## BMR Medicine

### Case Study

## A Giant Cystic Hygroma in Adult – A Surgical Challenge

Ameya Bihani, Jaini Lodha, Yogesh Dokhe, Priyanka Hardikar, Arpit Sharma and Jyoti Dabholkar

Department of ENT, KEM Hospital, Mumbai, India

Correspondence should be addressed to Ameya Bihani

Received 20 October 2014; Accepted 28 October 2014; Published 3 November 2014

Copyright: © 2014 Ameya Bihani et al. This is an open access article distributed under the Creative Commons Attribution License, which permits unrestricted use, distribution, and reproduction in any medium, provided the original work is properly cited.

### Abstract

Cystic hygroma is a type of lymphangioma which generally seen in infant. In adults, less than 150 cases have been reported in the literature. We present here a case of 27 year old male having giant cystic hygroma in neck with extension into mediastinum.

**Key words:** cystic hygroma, mediastinum, sclerotherapy

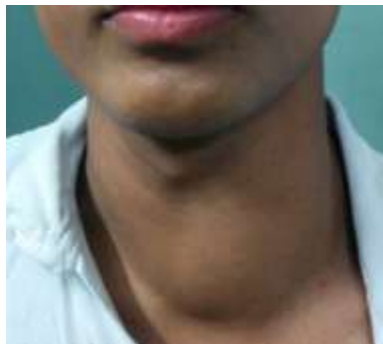### Introduction

Cystic hygroma (lymphangioma) is a benign congenital malformation of the lymphatic system that occurs as a result of sequestration or obstruction of developing lymphatic vessels.[1,2] These lesions are usually discovered in infant or children younger than two years of age.

Occurrence in adults is uncommon, and fewer than 150 cases of adult lymphangioma have been reported in the literature.[3-5]. Here we present a case of 27 year old male with cystic hygroma in neck since last 10 years.

### Case report

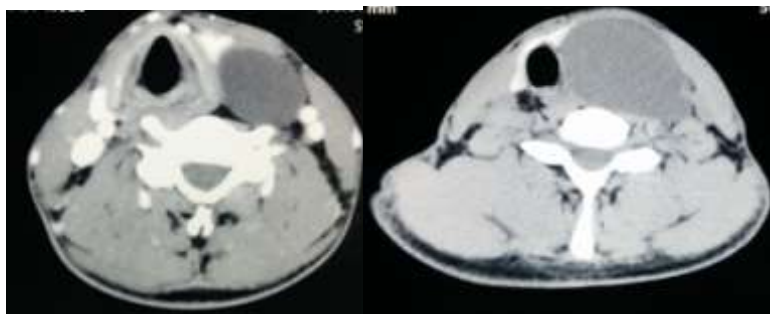
A 27 year old male presented with neck midline neck swelling since last 10 years which was small to start with and progressively increased in size in course of time. He complained of slight discomfort during eating food. There was no history of similar swelling since birth or any history of previous surgery or trauma. On examination, there was a soft cystic non tender swelling which extended from thyroid notch to sternum and laterally beneath the sternocleidomastoid of left side. The mass clinically appeared to have a retrosternal extension with absence of insinuation of fingers between the swelling and sternum. There was no movement of mass on deglutition. The Trachea was deviated to the right side.



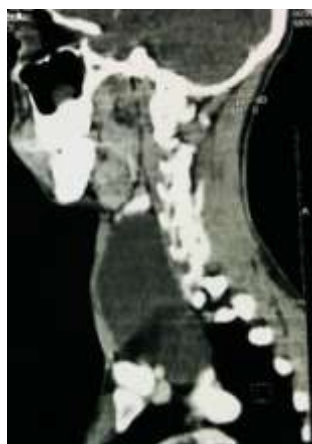**Fig 1.** Soft and cystic swelling presenting in the neck extending from the level of thyroid cartilage up to sternum

On fine needle aspiration, clear fluid with very few cells were obtained. On CT of neck, a soft tissue homogenous swelling with well defined margins was appreciated extending from the level of hyoid till the level just above arch of aorta. The mass was

seen to have an encroaching posterior mediastinal space. The mass was non enhancing on contrast. Trachea was shifted to right side with slightly compromised lumen. The carotid artery was anterolaterally.



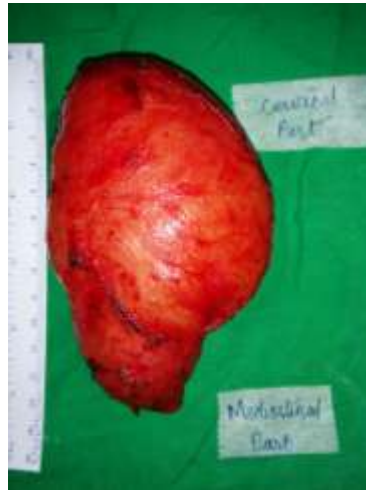**Fig 2 and 3.** CT showing the homogenous non enhancing mass with displacement of carotid posterolaterally



**Fig 4.** Sagittal frame of CT showing the lower extent of the swelling encroaching mediastinum

The patient was taken up for excision of mass. Under general anaesthesia, a horizontal incision was taken in the neck crease. The subplatysmal flaps were elevated. The swelling was delineated except in the region of inferior extent. The meticulous dissection was done with separation

and delineation of great vessel and vagus nerve was done. The swelling was dissected off the oesophagus and with traction was peeled out from the mediastinum. The histopathological report confirmed it to be a cystic hygroma.



**Fig 5.** Cystic hygroma specimen

## Discussion

Cystic hygroma is a subtype of lymphangioma which generally presents as either as congenital anomaly or within 2 years of birth. The incidence of cystic hygroma is very rare in adults and less than 150 cases have been reported in the literature. The primitive lymph sacs develop in mesoblast at about the sixth week of embryonic life, the principal pair being situated in the neck between the jugular and subclavian veins. It probably arises either from sequestration of primitive embryonic lymphatic tissue (jugular lymph sac) or from a congenital blocking of the regional lymph drainage [6,7].

Cystic lymphangioma occurs approximately 1 in 12000 births. Although the lesion can occur anywhere, the most common sites are in the posterior triangle of the neck (75%), axilla (20%), mediastinum (5%), groin, retroperitoneal space and pelvis [8]. This disease may be associated with Turner syndrome, Noonan syndrome, cardiac anomalies, trisomy syndromes and fetal hydrops.

Histologically, cystic hygromas are lymph filled cyst which is lined by single layer of endothelium which may be unilocular or multilocular. The lymph has scarce cell population.

The course of the disease is slowly progressive and generally present with swelling in the region with occasionally difficulty in breathing and swallowing.

Radiological investigation are commonly used for diagnosing the extent of the disease. In majority group of patients, this disease is present at birth. On antenatal ultrasound they may present as a nuchal cyst and may show septations +/- evidence of fetal anasarca/hydrops fetalis. The presence of septations may indicate a poorer outcome. Greater volumes ( $>75 \text{ mm}^3$  according to one study [9]) are thought to correlate with increased karyotypic abnormality and poorer fetal outcome [9-10]. In adults, USG findings are suggestive of fluid filled cystic cavity with or without loculation. On CT, it is commonly seen as a hypo-attenuating ill defined cystic mass. On MRI, it presents with predominantly low attenuating signals on T1 with predominantly high signal on T2. There is no enhancement on administration of contrast.

Management of cystic hygroma consists of either surgery or sclerotherapy.

Surgery of large cystic hygromas is very challenging in prospective of having vital structures in periphery. There is risk of injury to great vessels of neck or subclavian vessels. Nerves like vagus, recurrent laryngeal nerve, phrenic nerve are at risk of injury during surgical dissection.

Sclerotherapy agents which are generally used are Bleomycin and OK-432 and rarely corticosteroids or 50% dextrose.

Orford *et al* used intralesional bleomycin as a sclerosant in 16 patients and found excellent (complete clinical resolution) response in 44% cases, good response (more than 50% response) in 44% cases and poor or no response in 12% cases [14]. This therapy was without serious adverse effects. The only side effects which were observed were fever, vomiting, cellulitis and skin discoloration, and that too in a very few cases. So, bleomycin therapy is effective with a response rate comparable to that of surgical removal, and with the advantage of avoiding inadvertent nerve damage and scarring.

Ogita *et al* evaluated the mechanism of OK-432 (lyophilized incubation mixture of group A *Streptococcus pyogenes* of human origin) therapy in six patients with cystic hygroma and found that it induced and activated white blood cells (WBC) which produce cytokines [15]. These cytokines increase the endothelial permeability and thus accelerate lymph drainage and increased lymph flow leads to shrinkage of cystic spaces.

Different authors have quoted success rates of between 36 to 63% for complete tumour regression, of up to 88% significant lesion regression, and poor response of between 12 to 23% using either bleomycin or OK-432.

## Conclusion

Cystic hygroma is commonly known disease in paediatric population but is very rare in adults. There are various modalities of treatment of cystic hygroma but complete surgical excision is the best mode of treatment. Giant cystic hygroma with extension into mediastinum is a surgical challenge but comprehensive knowledge of anatomy with meticulous surgical dissection is key for successful complete excision.

**Conflict of interest** -nil

## References

1. Bloom DC, Perkins JA, Manning SC. Management of lymphatic malformations. *Curr Opin Otolaryngol Head Neck Surg* 2004; 12: 500–4. PMID: 15548907.
2. Naidu SI, McCalla MR. Lymphatic malformations of the head and neck in adults: a case report and review of the literature. *Ann OtolRhinolLaryngol* 2004; 113: 218–22. PMID: 15053205.
3. Gow L, Gulati R, Khan A, Mihaimed F (2011). Adult-onset cystic hygroma: a case report and review of management. *Grand Rounds* 11: 5–11. doi:10.1102/1470-5206.2011.0002.
4. Sherman BE, Kendall K. A unique case of a large cystic hygroma in the adult. *Am J Otolaryngol* 2001; 22: 206- 210.
5. Suk S, Sheridan M, Saenger JS. Adult lymphangioma: a case report. *Ear Nose Throat J* 1997; 76: 881-883.
6. Russell RC, Williams NS, Bulstrode . In: Bailey and Love's Short Practice of Surgery. 23rd ed. Arnold, editor. London and USA Oxford University Press; 2000. pp. 700–1.
7. Shahriari A, Odell JA. Cervical and thoracic components of multiorganlymphangiomas managed surgically. *Ann Thorac Surg*. 2001;71:694–6.
8. Woods D, Young JE, Filice R, Dobranowski J. Late-onset cystic hygromas: the role of CT. *Can Assoc Radiol J* 1989; 40:159-161.
9. Rosati P, Guariglia L. Prognostic value of ultrasound findings of fetal cystic hygroma detected in early pregnancy by transvaginal sonography. *Ultrasound Obstet Gynecol*. 2000;16 (3): 245-50.
10. Rosati P, Guariglia L. Transvaginal ultrasound detection of septated and non-septated cystic hygroma in early pregnancy. *Fetal. Diagn. Ther.* 12 (3): 132-5.
11. Ogita S, Tsuto T, Deguchi E, Tokiwa K, Nagashima M, Iwai N. OK-432 therapy for

unresectable lymphangiomas in children. *J Pediatr Surg* 1991; 26: 263-270.

12. Neilsen LH, Charabi B, Jensen F, Cleasson G, Bretlau P. Cystic Hygroma: OK-432 is superior to surgery. *International Congress Series* 2003; 1254: 519-522.

13. Ruiz Jr E, Valera ET, Verissimo F, Tone LG. OK-432 therapy for lymphangioma in children, *Jornal de Pediatria* 2004; 80(2): 154-158.

---

14. Orford J, Barker A, Thonell S, King P, Murphy J. Bleomycin therapy for cystic hygroma. *J Pediatr Surg*. 1995;30:1282-7

15. Ogita S, Tsuto T, Nakamura K, Deguchi E, Tokiwa K, Iwai N. OK-432 therapy for lymphangioma in children: Why and how does it work? *J Pediatr Surg*. 1996;31:477-80

---