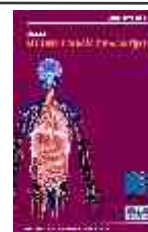



JRAAS

Special Issue in Medicine & Surgery

www.internationalmedicalpublishing.com



Research Article

Section: Radiodiagnosis

Role of Magnetic Resonance Imaging in Non-Traumatic Hip Pain

Dr. Shashank G. R.¹, Dr. Sowmya Anand*² & Dr. Sanjay S. C.³

¹Junior Resident, Department of Radiodiagnosis, Kempegowda Institute of Medical Sciences Bangalore

²Assistant Professor, Department of Radiodiagnosis, Kempegowda Institute of Medical Sciences Bangalore

³Professor and HOD, Department of Radiodiagnosis, Kempegowda Institute of Medical Sciences Bangalore

HIGHLIGHTS

- Early detection of hip pathologies
- Superior soft tissue contrast resolution
- Identifies avascular necrosis reliably
- Differentiates inflammatory and infectious causes
- Guides management and surgical planning
- Detects occult fractures and edema
- MRI avoids radiation, non-invasive method

ARTICLE INFO

Handling Editor: Dr. Sandeep Singh

Key Words:

Diabetic foot disease
Ultrasound
MRI
Early diagnosis
Radiological imaging

ABSTRACT

Aim: This study aims to evaluate the role of Magnetic Resonance Imaging (MRI) in diagnosing non-traumatic hip pain, focusing on identifying various pathologies, including Avascular Necrosis (AVN), and assessing MRI's diagnostic accuracy. **Introduction:** Non-traumatic hip pain can arise from several musculoskeletal and systemic conditions, with Avascular Necrosis (AVN) being one of the most common causes. MRI has become the preferred modality for evaluating hip pathologies due to its ability to provide detailed images of both bone and soft tissue structures. This study investigates the role of MRI in diagnosing these conditions and identifies the prevalence of different hip disorders. MRI is essential not only for detecting common issues like AVN but also for identifying rare conditions, such as tumors and infections, that contribute to hip pain. **Materials and Methods:** A descriptive study was conducted in the Department of Radiodiagnosis at Kempegowda Institute of Medical Sciences (KIMS), Bangalore, from July to December 2023. A total of 43 patients (28 males, 15 females) with non-traumatic hip pain underwent MRI evaluation to identify the underlying causes of their symptoms. **Results:** The most common diagnosis was Avascular Necrosis (AVN), with 30.2% of cases having bilateral AVN. The study also identified AVN (unilateral) in 9.3% of patients. Additionally, tumors such as metastasis/myeloma accounted for 4.6% of cases. Other diagnoses included trochanteric bursitis, hip joint synovitis, and tubercular arthropathy. MRI was critical in diagnosing these conditions, particularly AVN, and was instrumental in early-stage detection. **Conclusion:** MRI plays a vital role in diagnosing non-traumatic hip pain, particularly Avascular Necrosis. It offers superior diagnostic accuracy, allowing for early detection of hip disorders, including tumors, infections, and other musculoskeletal pathologies. Early diagnosis through MRI enables timely interventions, improving patient outcomes and preventing further complications.

*Corresponding Author: Dr. Shashank G. R., Department of Radiodiagnosis, Kempegowda Institute of Medical Sciences Bangalore

E-mail: shashank.gr95@gmail.com Article History: Received 24 June 2025; Received in Revised form 29 July 2025; Accepted 05 August 2025

How To Cite: Shashank G. R., Role of Magnetic Resonance Imaging in Non-Traumatic Hip Pain .JRAAS: Special Issue in Medicine & Surgery.2025;40(1),1-6

INTRODUCTION

Hip pain is a prevalent complaint among adults, especially in older populations, where non-traumatic cases affect approximately 14% of individuals over the age of 60[1]. The hip joint, being a major weight-bearing structure in the body, is crucial for maintaining mobility and function. It is susceptible to a wide variety of pathologies that can lead to chronic pain and dysfunction. These pathologies can be categorized into intra-articular, peri-articular, and extra-articular conditions, each with distinct etiologies and diagnostic challenges[2]. Despite its central role in human movement, diagnosing the cause of non-traumatic hip pain remains a significant clinical challenge, often requiring advanced imaging techniques to identify the underlying pathology.

Intra-articular causes of hip pain include conditions like avascular necrosis (AVN), arthritis, loose bodies, and labral tears, which often result in cartilage damage, subchondral bone changes, or joint effusion[3]. On the other hand, peri-articular causes such as tendonitis and bursitis can result from overuse or inflammatory conditions, affecting the surrounding soft tissues and leading to pain and limited mobility. Extra-articular causes, including referred pain from the lumbar spine or sacroiliac joint, complicate the diagnosis, as they may present with symptoms similar to those originating directly from the hip joint.[4]

A key difficulty in diagnosing non-traumatic hip pain lies in the often subtle and nonspecific nature of clinical and radiographic findings[5]. Traditional X-rays are typically the first-line imaging modality; however, they may fail to detect early or subtle pathologies, particularly in cases of AVN or early-stage arthritis. Radiographs may also appear normal in certain instances of hip dysplasia, infections, or occult fractures, leading to potential misdiagnosis or delayed treatment. This limitation underscores the importance of using advanced imaging modalities that can offer better diagnostic accuracy and insight into the complex anatomy of the hip joint and surrounding structures.

One of the most significant advancements in musculoskeletal imaging has been the development of Magnetic Resonance Imaging (MRI). MRI is a non-invasive imaging technique that provides high-resolution images of both osseous and soft tissue structures, making it highly effective for evaluating a wide range of hip disorders. MRI allows for detailed visualization of articular cartilage, subchondral bone, synovial membranes, muscles, ligaments, and the joint capsule, making it invaluable in diagnosing conditions that may not be visible on plain radiographs. Moreover, MRI has a distinct advantage in identifying early joint changes such as cartilage degeneration, subchondral bone edema, and synovial fluid accumulation, which are often

precursors to more severe hip pathologies.

In cases of non-traumatic hip pain, MRI plays a pivotal role not only in diagnosing intra-articular conditions like AVN and arthritis but also in detecting peri-articular and extra-articular pathologies such as tendonitis, bursitis, and referred pain from spinal disorders. The ability of MRI to provide multi-planar imaging (coronal, sagittal, and axial views) allows for a comprehensive evaluation of both hips in a symmetric manner, offering valuable insights into conditions that affect one or both sides. This is particularly useful in conditions like hip dysplasia, which can affect both hips asymmetrically[6].

The increasing availability of high-field MRI machines with improved image quality and shorter scan times has further enhanced the utility of MRI in clinical practice. Additionally, contrast-enhanced MRI and specialized techniques like magnetic resonance arthrography (MRA) have improved the diagnostic accuracy for complex joint pathologies, such as labral tears, cartilage defects, and loose bodies, which may not be readily apparent on conventional MRI scans.

This study aims to explore the role of MRI in diagnosing non-traumatic hip pain, highlighting its importance in identifying various pathologies that are often missed or inadequately characterized by traditional radiographic techniques. By evaluating the accuracy of MRI compared to plain radiography in a cohort of patients with non-traumatic hip pain, the study seeks to underscore the diagnostic superiority of MRI in managing these challenging cases. Furthermore, understanding the relationship between MRI findings and clinical presentations will help guide treatment decisions and improve patient outcomes[7].

Given the complexity of the hip joint and the diverse range of conditions that can lead to pain, MRI has become an indispensable tool for clinicians in providing accurate diagnoses, developing appropriate treatment plans, and monitoring disease progression. This paper will review the various hip pathologies detectable by MRI and discuss the specific advantages of MRI over traditional imaging modalities in the context of non-traumatic hip pain.

MATERIALS AND METHODS

This descriptive, prospective study was conducted in the Department of Radiodiagnosis at Kempegowda Institute of Medical Sciences (KIMS) Hospital, Bangalore, over a period of six months, from July 2023 to December 2023. A total of 43 patients, both adults and children, presenting with non-traumatic hip pain, were included in the study. All patients underwent MRI imaging of the hip joint, and the resulting scans were reviewed to identify intra-articular and extra-articular pathologies. The MRI findings were compared with clinical diagnoses to assess the diagnostic accuracy and effectiveness of MRI as a modality for non-traumatic hip pain. Ethical clearance for the study was obtained from the institutional ethics committee, and informed

consent was taken from all patients or their guardians prior to participation. The study adhered to standard ethical practices and radiological protocols throughout its course.

RESULTS

The study evaluated 43 patients with non-traumatic hip

pain using Magnetic Resonance Imaging (MRI) to diagnose various hip joint pathologies. The gender distribution revealed a higher prevalence of non-traumatic hip pain in male patients (65.1%) compared to female patients (34.9%).(Table 1)

Table 1: Gender distribution among patients having non traumatic hip pain

Gender	Number of Patients (N)	Percentage (%)
Male	28	65.10%
Female	15	34.90%

The most common chief complaint in our patients was bilateral avascular necrosis in 13 (30.2%) patients followed by sacroiliitis and unilateral avascular necrosis with 5 & 4 (11.6 and 9.3%) patients respectively. Other presenting pathologies were hip joint synovitis 3(6.9%), trochanteric bursitis 3 (6.9%), osteoarthritis 2 (4.6%),

erosive arthritis 1 (2.3%), septic arthritis 1 (2.3%) tubercular arthropathy 1 (2.3%) slipped capital femoral epiphysis 1 (2.3%), developmental dysplasia of hip 1 (2.3%), osteochondroma 2 (4.6%), transient osteoporosis of hip 2 (4.6%), primary bone tumor/ metastasis pathological fracture 2 (4.6%), joint effusion with marrow edema 1 (2.3%). (Table 2)

Table 2: Clinical Prevalence of Hip Pathologies

Hip Pathology	Total (N = 43)	Percentage
Avascular Necrosis (Bilateral)	13	30.2%
Avascular Necrosis (Unilateral)	4	9.3%
Trochanteric Bursitis	3	6.9%
Sacroiliitis (Including Enthesopathy)	5	11.6%
Hip Joint Synovitis	3	6.9%
Osteoarthritis	2	4.6%
Osteochondroma	2	4.6%
Transient Osteoporosis of Hip	2	4.6%
Slipped Capital Femoral Epiphysis	1	2.3%
Tubercular Arthropathy	1	2.3%

Among 43 patients the most common pathology encountered was bilateral avascular necrosis with a total of 17 cases (39.5%). Bilateral AVN was more common in males (9 out of 28 male patients, 32.1%) compared to females (4 out of

15 female patients, 26.7%). Followed by Sacroiliitis (Including Enthesopathy) (14.3%), Trochanteric Bursitis (7.1%), Hip Joint Synovitis (7.1%), Unilateral AVN (10.7%) reported higher incidence in males compared to females. (Figure 1)

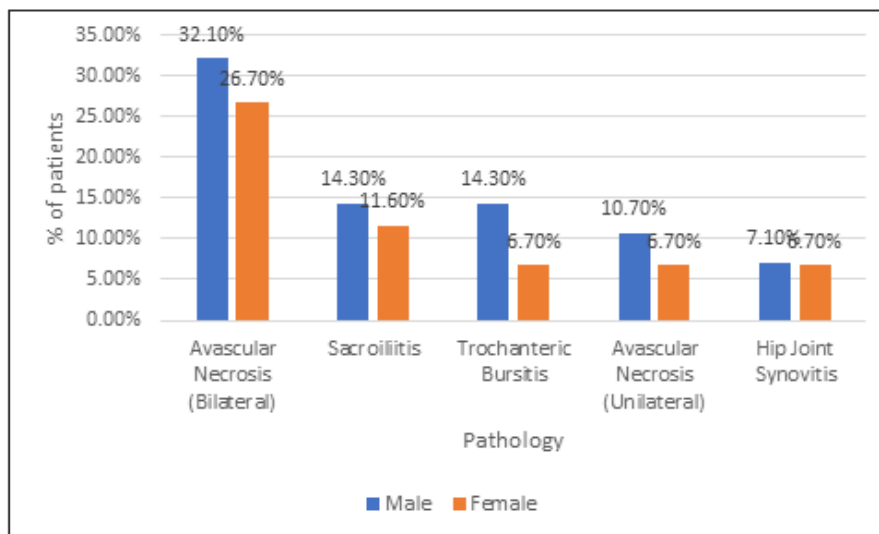


Figure 1. Gender differences in most prevalent pathology diagnosed by MRI

MRI also identified pathological fractures due to primary bone tumors including metastasis/myeloma and osteochondroma. The most common tumor diagnosis was

osteochondroma, seen in 4.6% of the patients, followed by primary bone tumors/metastasis and myeloma, each accounting for 4.6% and 2.3%, respectively. (Table 3)

Table 3: Prevalence and Distribution of Bone Tumors and Metastasis in Patients using MRI

Diagnosis	No. of Patients	Percentage
Osteochondroma	2	4.60%
Primary Bone Tumor / Metastasis (Pathological Fracture)	2	4.60%
Metastasis/Myeloma (Right Iliac Bone and Femur)	1	2.30%

DISCUSSION

Non-traumatic hip pain can result from a variety of musculoskeletal and systemic conditions. One of the most common causes of non-traumatic hip pain is Avascular Necrosis (AVN), which occurs when there is a disruption in the blood supply to the femoral head, leading to bone cell death. MRI has become a key diagnostic tool in identifying and evaluating hip pathologies, including AVN, due to its ability to provide detailed images of both bone and soft tissue structures.

In our study, Avascular Necrosis was the most common hip pathology identified, accounting for 39.5% of the cases. This finding is consistent with previous studies[8] who

emphasized that AVN is a major cause of chronic hip pain and can be easily detected using MRI, especially in the early stages when X-rays may not show significant changes [8]. In Chougule SR (2022) reported similar result with high prevalence of AVN in patients with non-traumatic chronic hip pain in a rural population, demonstrating MRI's diagnostic superiority in detecting AVN, even in its subclinical stages [9]. The ability of MRI to detect early-stage AVN, before significant bone collapse occurs, is crucial for timely intervention, as it allows for conservative management options that can help preserve hip function.

Furthermore, the prevalence of Bilateral Avascular Necrosis was significantly higher than Unilateral AVN in our

study, which aligns with findings from literature, who noted that bilateral AVN is more commonly seen in systemic conditions such as corticosteroid use, alcohol abuse, and certain autoimmune diseases [10]. In our cohort, 30.2% of patients had bilateral AVN, while 9.3% had unilateral AVN. This is significant, as bilateral AVN often presents with more severe symptoms and can lead to rapid joint degeneration, necessitating early diagnosis and intervention.

Interestingly, the results of our study showed a higher prevalence of AVN in male patients compared to female patients. Specifically, 42.9% of male patients had AVN, compared to 33.3% of female patients. This finding is in line with several studies that report a higher incidence of AVN in men, particularly in younger populations. Male patients are more likely to develop AVN due to factors such as trauma, alcohol use, and systemic diseases like sickle cell anemia, which are more common in men [9]. Additionally, found that men in the age group of 30-50 years were more frequently diagnosed with AVN, which corresponds to our findings of a higher incidence in male patients [10]

In this study, MRI also revealed tumor-related pathologies, including osteochondroma and metastasis, which were observed in 9.2% of patients. The ability of MRI to detect these conditions underscores its value in identifying not only common hip disorders like AVN but also rare pathologies such as primary bone tumors and metastatic lesions, aligning with findings from previous studies [9,10]

MRI is the gold standard for diagnosing AVN due to its high sensitivity and specificity in detecting bone marrow edema, the early sign of AVN. In our study, MRI was essential in identifying AVN in patients presenting with non-traumatic hip pain, especially in cases where X-rays failed to show significant abnormalities. Early detection of AVN through MRI allows for the initiation of treatments aimed at halting the progression of the disease and preventing joint collapse, ultimately improving the patient's prognosis.

The ability of MRI to visualize the subchondral bone, joint effusions, and soft tissue changes provides critical information for determining the stage of AVN and helps guide treatment decisions, from conservative management to surgical options such as core decompression or total hip replacement. As noted by earlier studies, MRI is particularly helpful in diagnosing early-stage AVN, where radiographic changes are not yet evident but where the patient may already experience significant pain and functional limitation [8].

CONCLUSION

Magnetic Resonance Imaging (MRI) plays a critical role in diagnosing non-traumatic hip pain, particularly in detecting conditions like Avascular Necrosis (AVN). This study found that AVN, especially bilateral AVN, was the most prevalent pathology, with a higher incidence in male patients.

MRI's ability to detect early bone changes, joint effusions, and soft tissue abnormalities makes it superior to traditional radiography, especially in diagnosing AVN in its initial stages. This early detection is vital for timely intervention and better outcomes, preventing further joint degeneration. MRI's non-invasive nature, combined with its detailed imaging capabilities, allows for accurate diagnosis and staging, which is essential for developing an appropriate treatment plan. Therefore, MRI should be considered the gold standard for evaluating non-traumatic hip pain, offering significant diagnostic advantages over other imaging modalities, especially in conditions like AVN.

REFERENCES

1. Battaglia PJ, D'Angelo K, Kettner NW. Posterior, Lateral, and Anterior Hip Pain Due to Musculoskeletal Origin: A Narrative Literature Review of History, Physical Examination, and Diagnostic Imaging. *J Chiropr Med.* 2016 Dec;15(4):281-93.
2. Department of Radiology Image Hospital, Hyderabad, Telangana-500083, Anu Kapoor KVR. MR Evaluation of Non-Traumatic Hip Pain. *jmscr* [Internet]. 2017 Mar 19 [cited 2024 Dec 5];05(03):19090–101. Available from: <http://jmscr.igmpublication.org/v5-i3/126%20jmscr.pdf>
3. Drar HAEAE, Mohammed BAED, Ali ZAEM. The Role of MRI in the Evaluation of Painful Hip Joint (MRI of Hip Joint). *Int J Med Imaging* [Internet]. 2014 May [cited 2024 Dec 5];2(3):77–82. Available from: <https://www.sciencepg.com/article/10.11648/j.ijmi.20140203.16>
4. Osman NM, Hemeda TW, Thabit MT. Role of Magnetic Resonance Imaging in the evaluation of adult non-traumatic painful hip. *Sohag Medical Journal* [Internet]. 2019 Apr 1 [cited 2024 Dec 5]; Available from: https://journals.ekb.eg/article_47675.html
5. Chhabra S, Kaur N, Bhatnagar S, Chhabra P, Puri S. MRI Evaluation of Painful Hip Joint: Asian Journal of Medical Radiological Research [Internet]. 2020 Jul 5 [cited 2024 Dec 5];8(1):122–7. Available from: <https://ajournals.com/index.php/ajmrr/article/view/1641>
6. Omar IM, Blount KJ. Magnetic Resonance Imaging of the Hip. *Top Magn Reson Imaging.* 2015 Aug;24(4):165–81.
7. Ghebonni L, Roger B, El-khoury J, Brasseur JL, Grenier PA. MR arthrography of the hip: normal intra-articular structures and common disorders. *Eur Radiol.* 2000;10(1):83–8.
8. Manaster BJ. Adult Chronic Hip Pain: Radiographic Evaluation. *RadioGraphics* [Internet]. 2000 Oct [cited 2024 Dec 5];20(suppl_1):S3–25. Available from: https://pubs.rsna.org/doi/abs/10.1148/radiographics.20.Suppl_1.G00oc06s3

9. Chougule SR. The role of magnetic resonance imaging in non-traumatic chronic hip joint pain in adult rural population. *International Journal of Research in Medical Sciences* [Internet]. 2022 Nov 25 [cited 2024 Dec 5];10(12):2821–5. Available from: <https://www.msjoonline.org/index.php/ijrms/article/view/11109>
10. Mak MS, Teh J. Magnetic resonance imaging of the hip: anatomy and pathology. *Pol J Radiol*. 2020;85:e489–508.